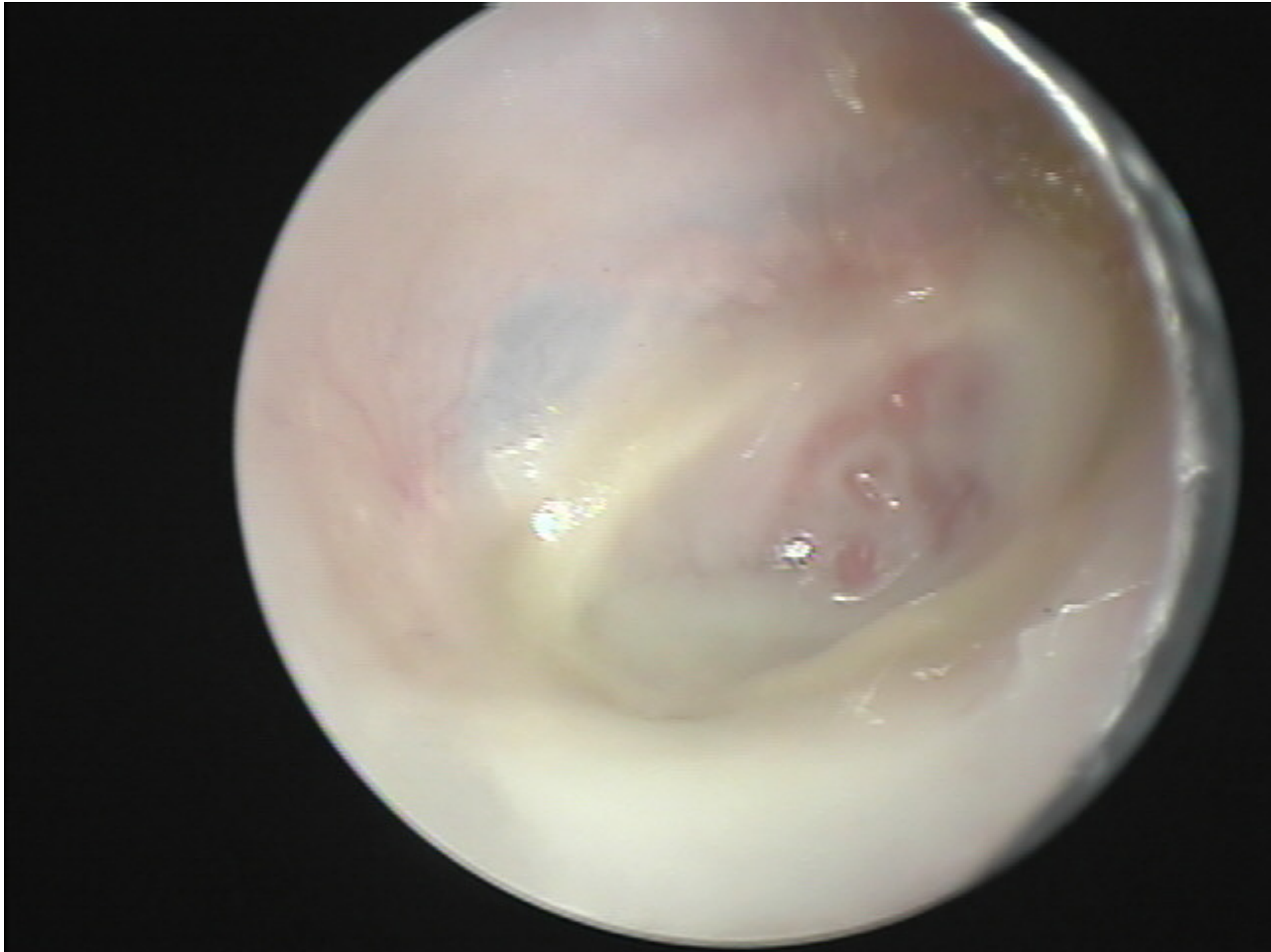

# The Draining Ear

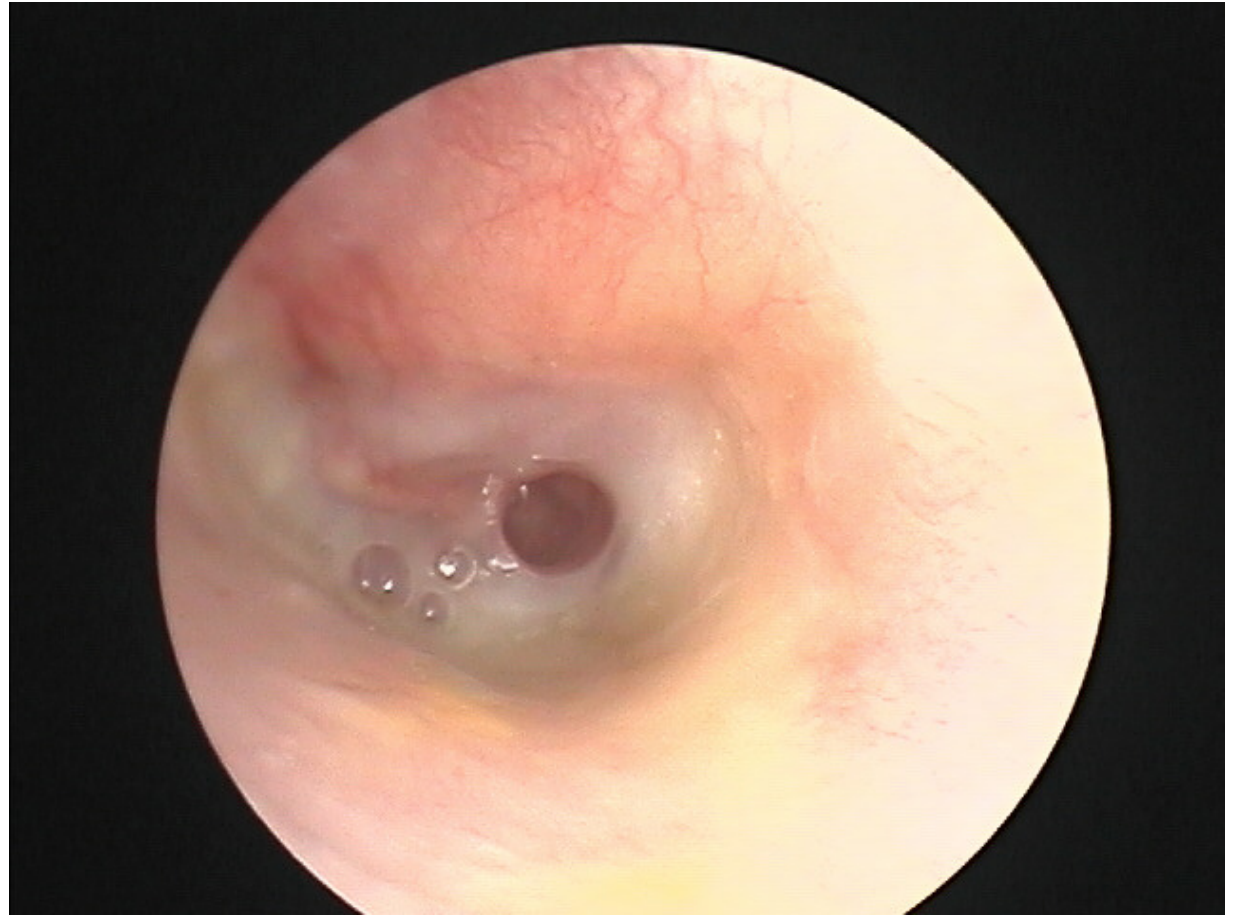


# Take home

- Where is the infection coming from
- How do I (we) best clean it
- How do I get the highest concentration of medication to the infected area

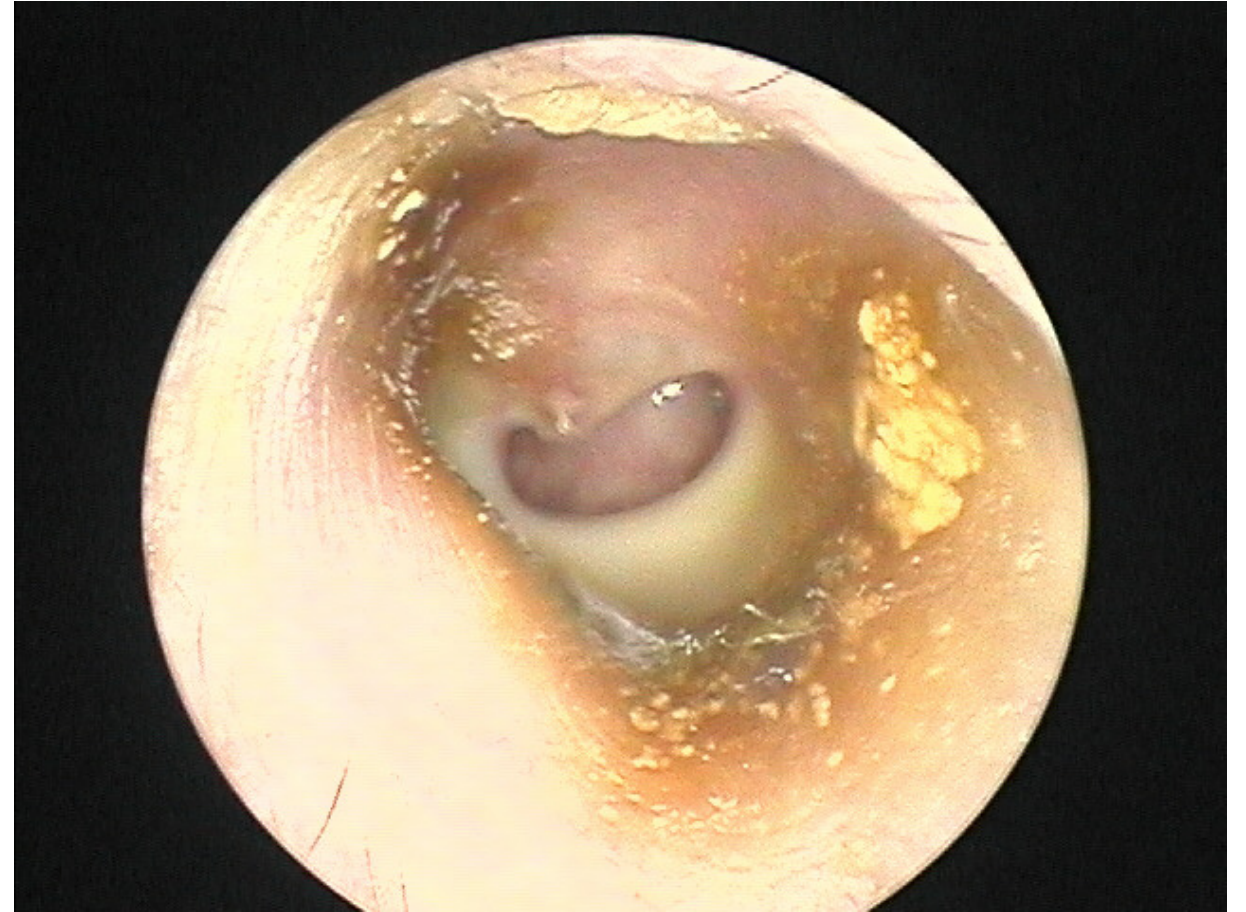
# What we are going to cover

- How to think about it
- How to categorize it
- How to treat it



# Disclaimer

- I know the literature
- I don't agree with all of it
- I'll try to indicate what are my views that are not shared



- We probably see more of this disease than anyone
- The disease we see is probably a little different than what is seen in Boston, Seattle, Atlanta, etc

## Otolaryngology -- Head and Neck Surgery

<http://oto.sagepub.com/>

---

### Clinical Practice Guideline: Acute Otitis Externa

Richard M. Rosenfeld, Seth R. Schwartz, C. Ron Cannon, Peter S. Roland, Geoffrey R. Simon, Kaparaboyna Ashok Kumar, William W. Huang, Helen W. Haskell and Peter J. Robertson  
*Otolaryngology -- Head and Neck Surgery* 2014 150: S1  
DOI: 10.1177/0194599813517083

The online version of this article can be found at:  
[http://oto.sagepub.com/content/150/1\\_suppl/S1](http://oto.sagepub.com/content/150/1_suppl/S1)

---

Published by:



<http://www.sagepublications.com>



American Academy of Otolaryngology- Head and Neck Surgery

Additional services and information for *Otolaryngology -- Head and Neck Surgery* can be found at:

Email Alerts: <http://oto.sagepub.com/cgi/alerts>

Subscriptions: <http://oto.sagepub.com/subscriptions>

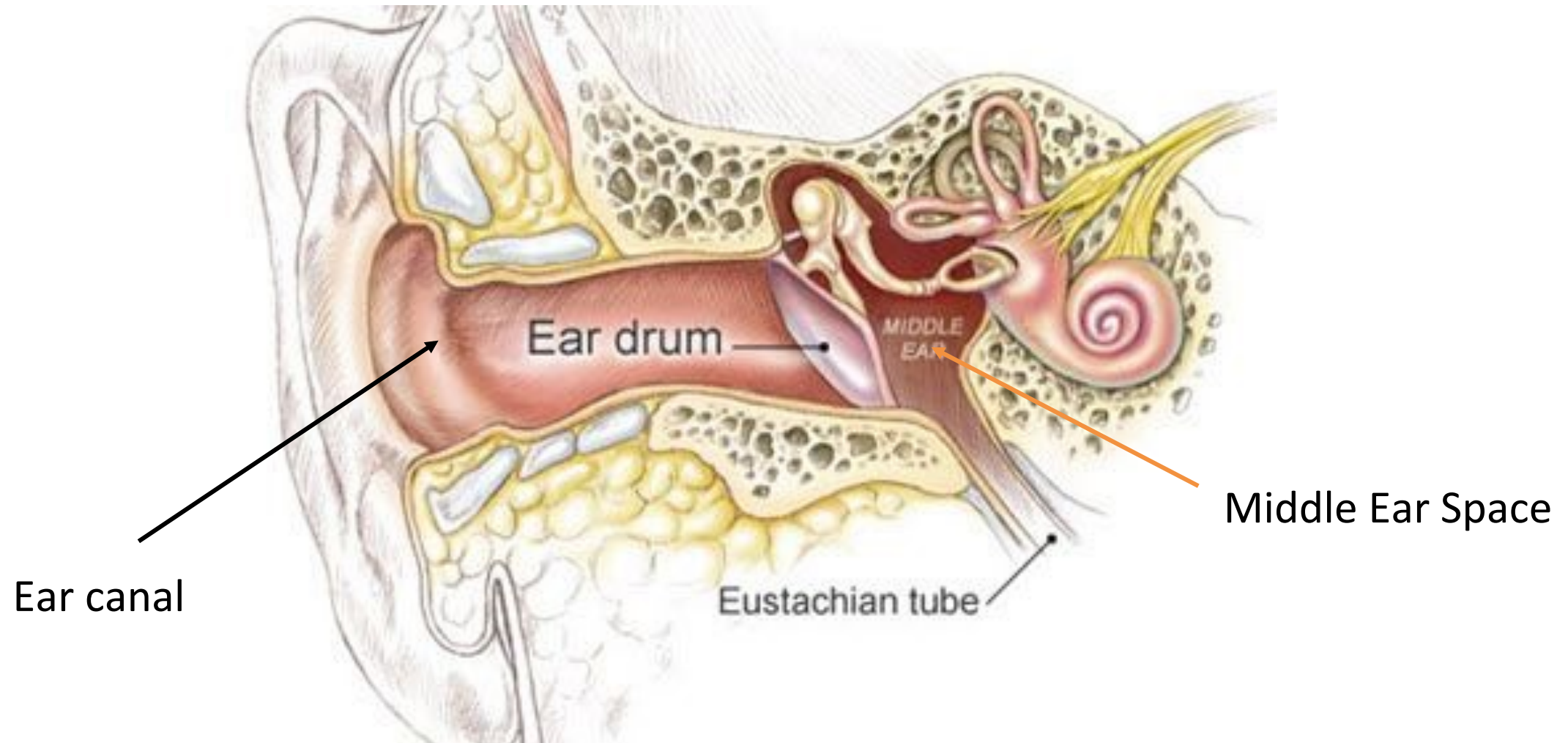Reprints: <http://www.sagepub.com/journalsReprints.nav>

Permissions: <http://www.sagepub.com/journalsPermissions.nav>

>> Version of Record - Feb 3, 2014

[What is This?](#)

All the anatomy you need to know (for today)



# Most important concepts of the day

- “An advantage of topical therapy is the very high concentration that can be delivered to the infected tissue, often 100 to 1000 times higher than can be achieved with systemic therapy.”
- “Topical therapy avoids prolonged exposure to subtherapeutic concentrations of antibiotic and may therefore be less likely than systemic therapy to result in selective pressure for resistant organisms.”

*AAO/HNS Clinical Practice Guidelines*

# Antibiotic concentrations

**Systemic antibiotics**



**Topical antibiotics OR antiseptics**

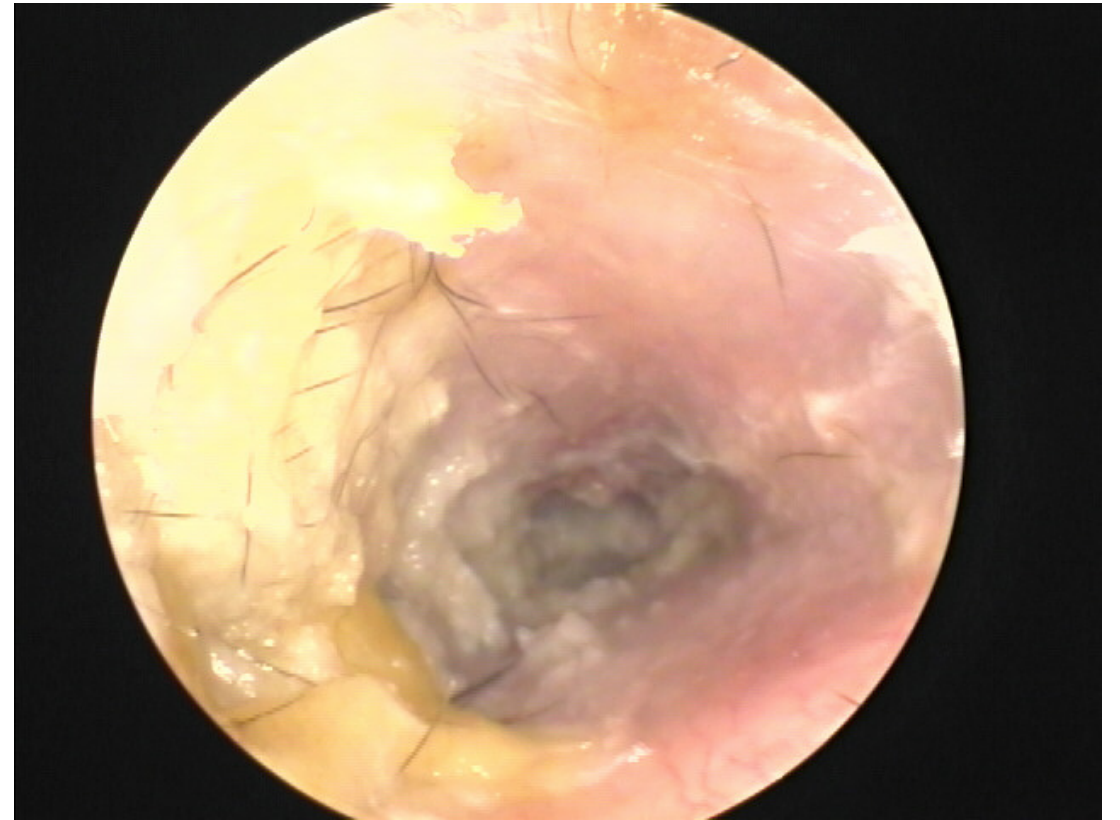


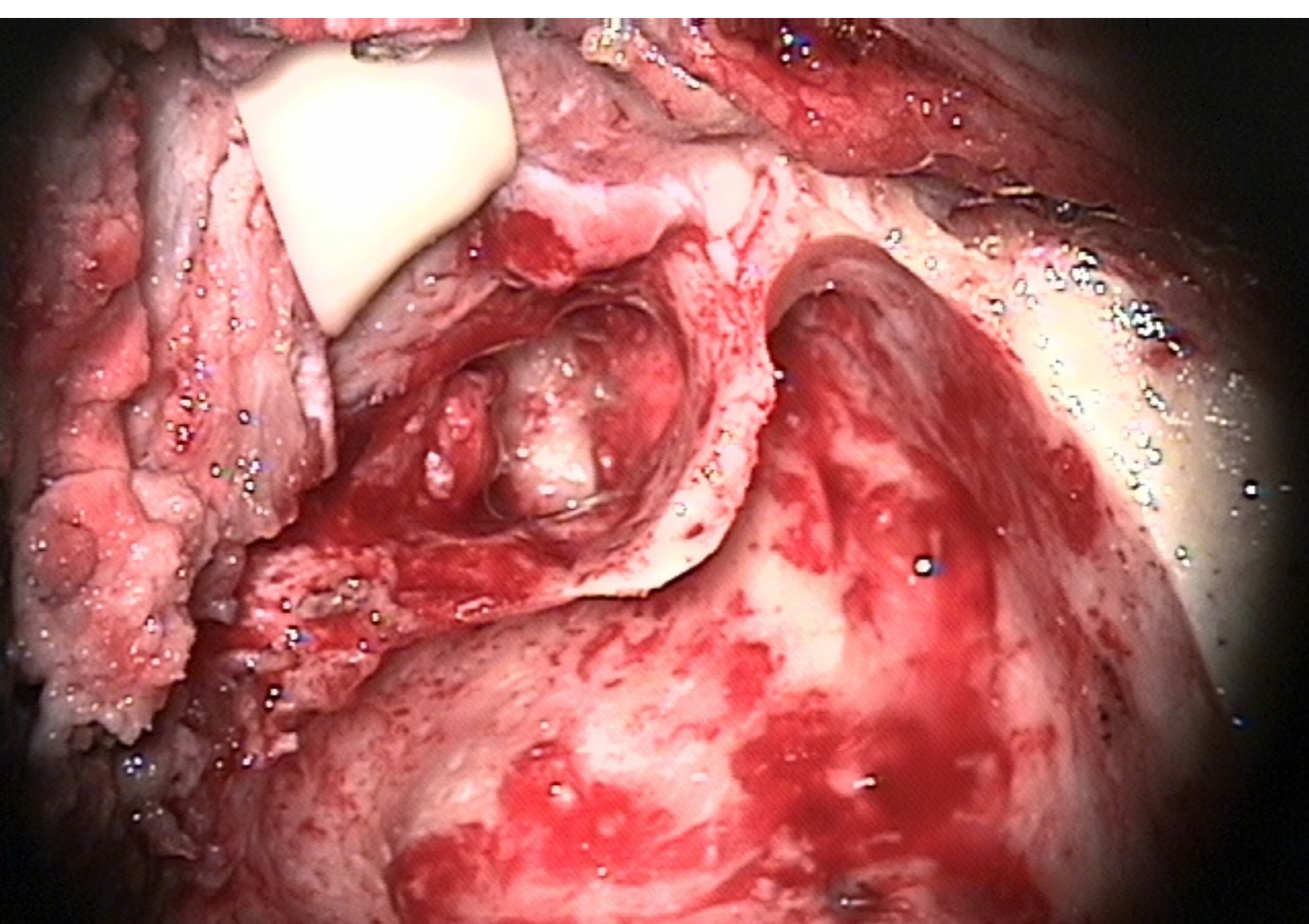
Whenever possible, use drops rather than pills or IV/IM meds.

- If you can get the drops to the infected tissue
- If the infection has not spread to peri-auricular soft tissues
- Back to this later

# How to think about the draining ear – it comes from one of three places

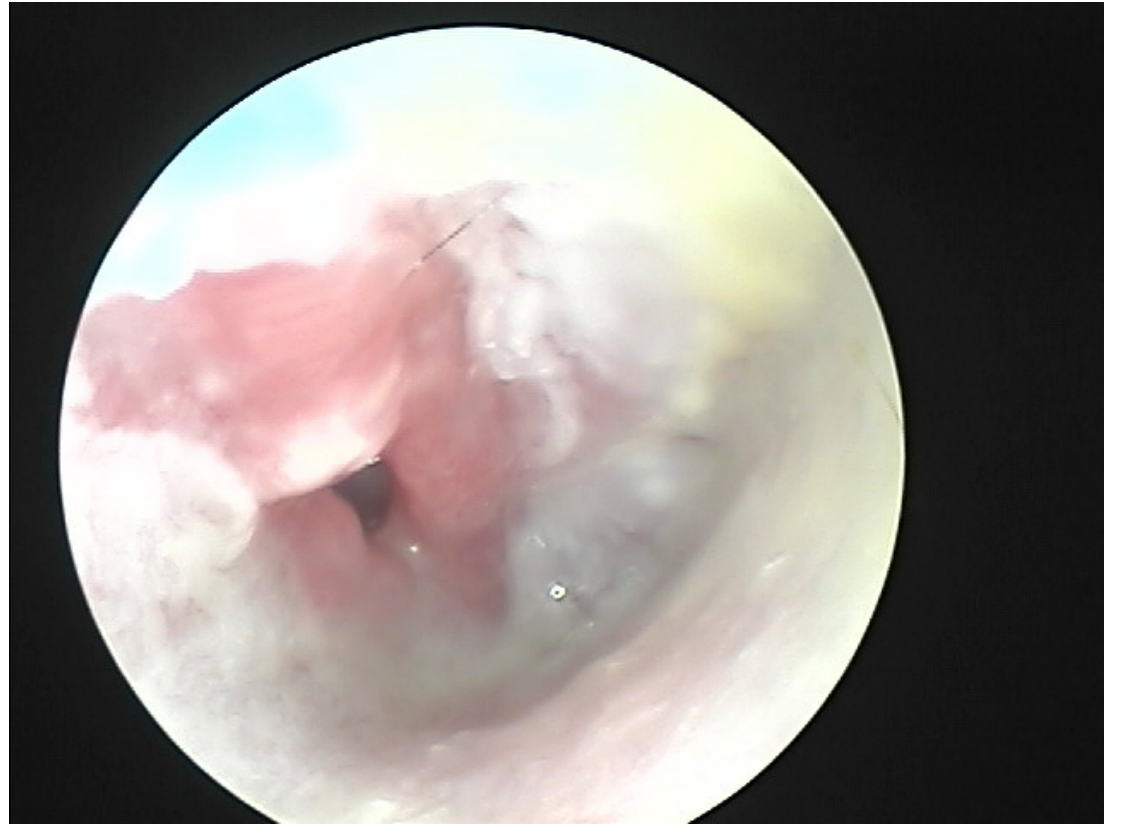
- Ear canal
- Surface of the tympanic membrane
- The middle ear space
- The middle ear space normally communicates with the mastoid





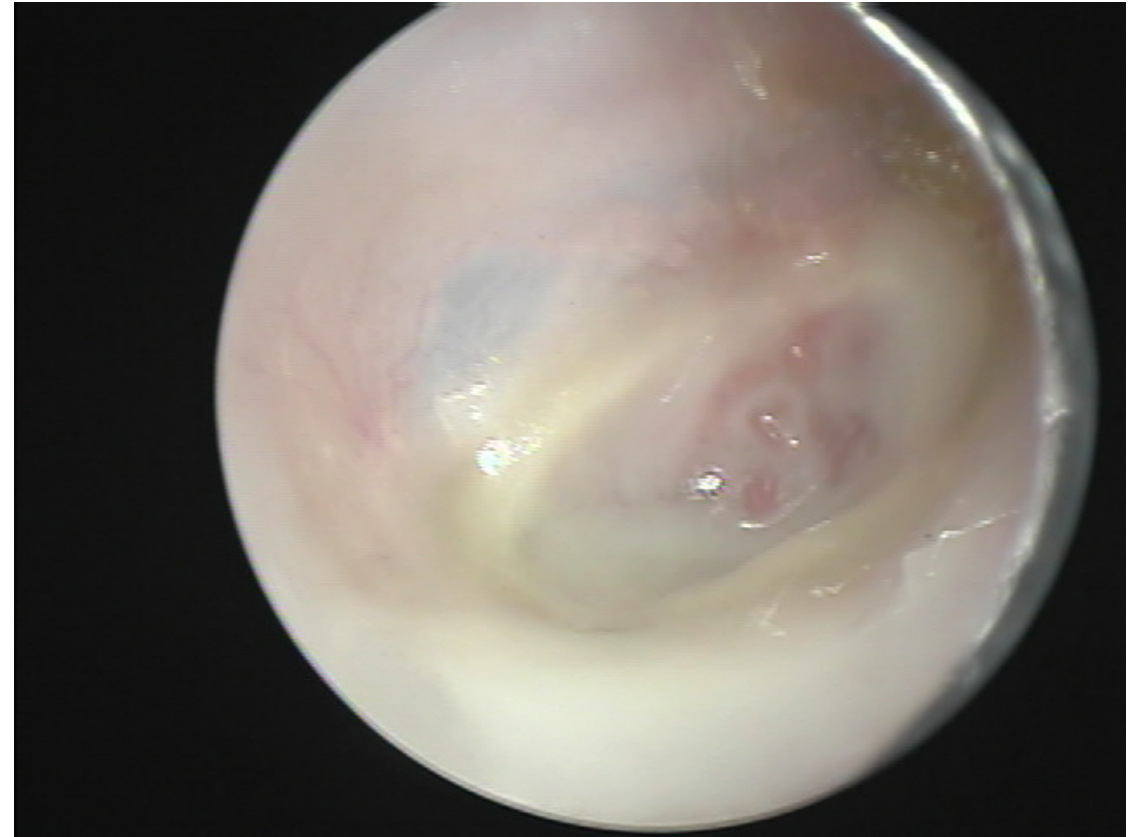# For each site

- What is the underlying problem
- How do I (we) clean it.
- How do I get the medication to the infected tissue

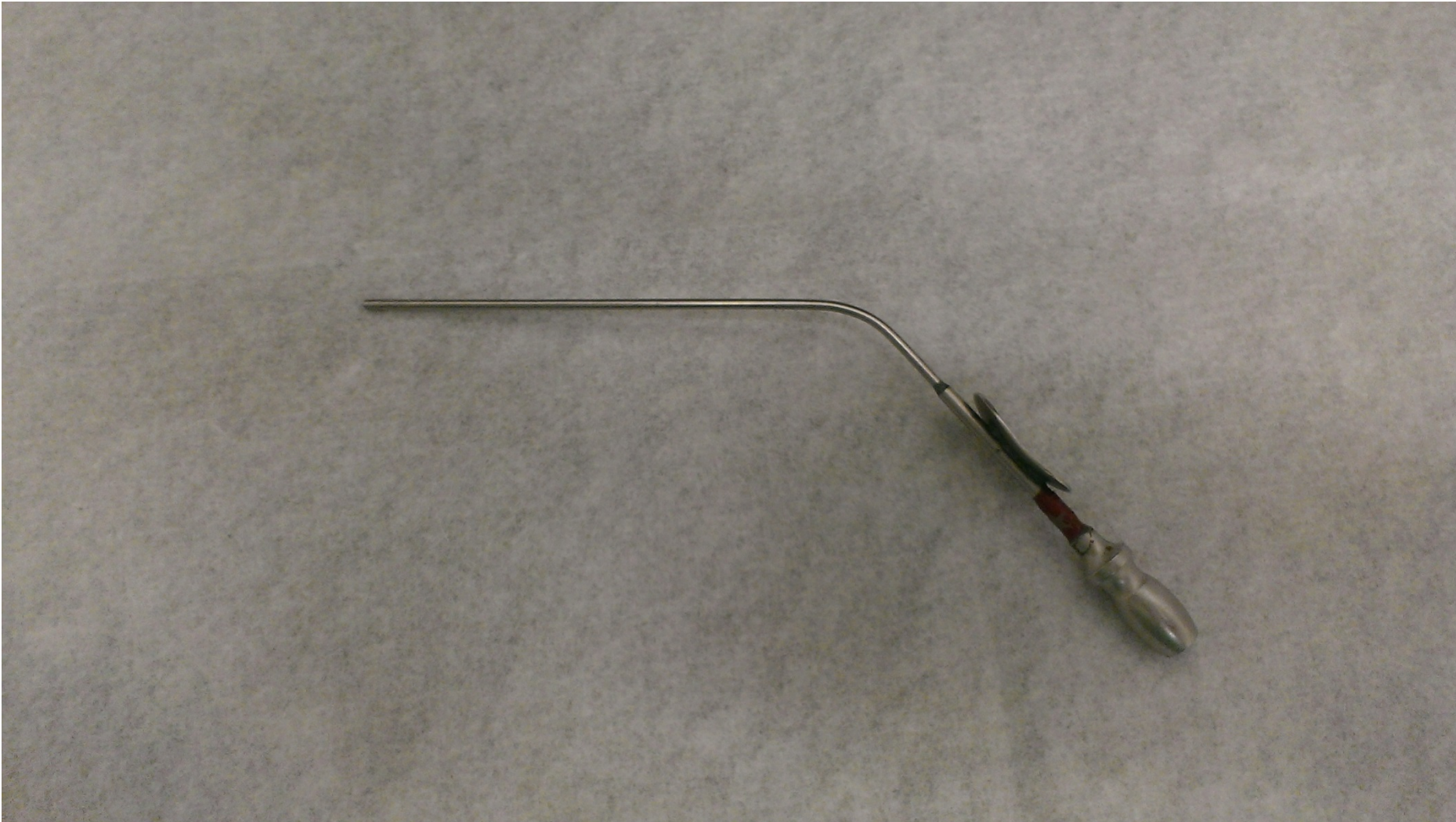


# Third important concept for today

- You can't diagnose or effectively treat a draining ear unless you can adequately clean it.



You have this here...

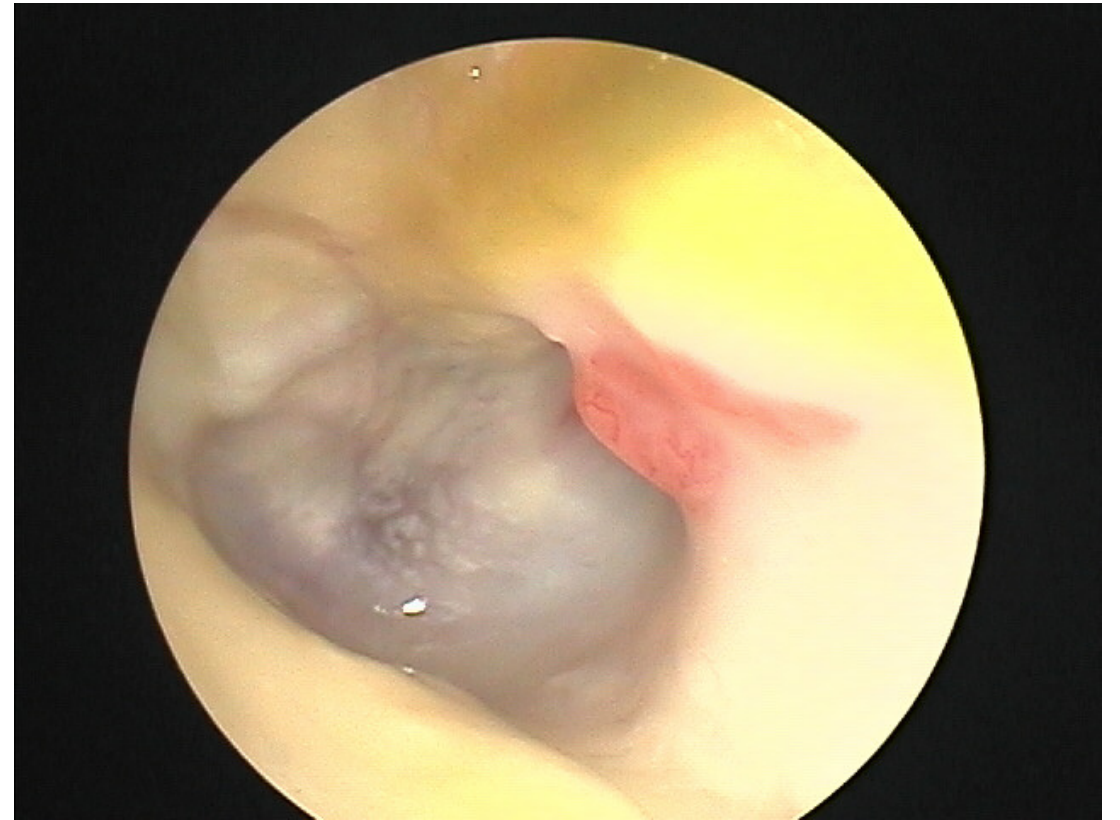


And you have this



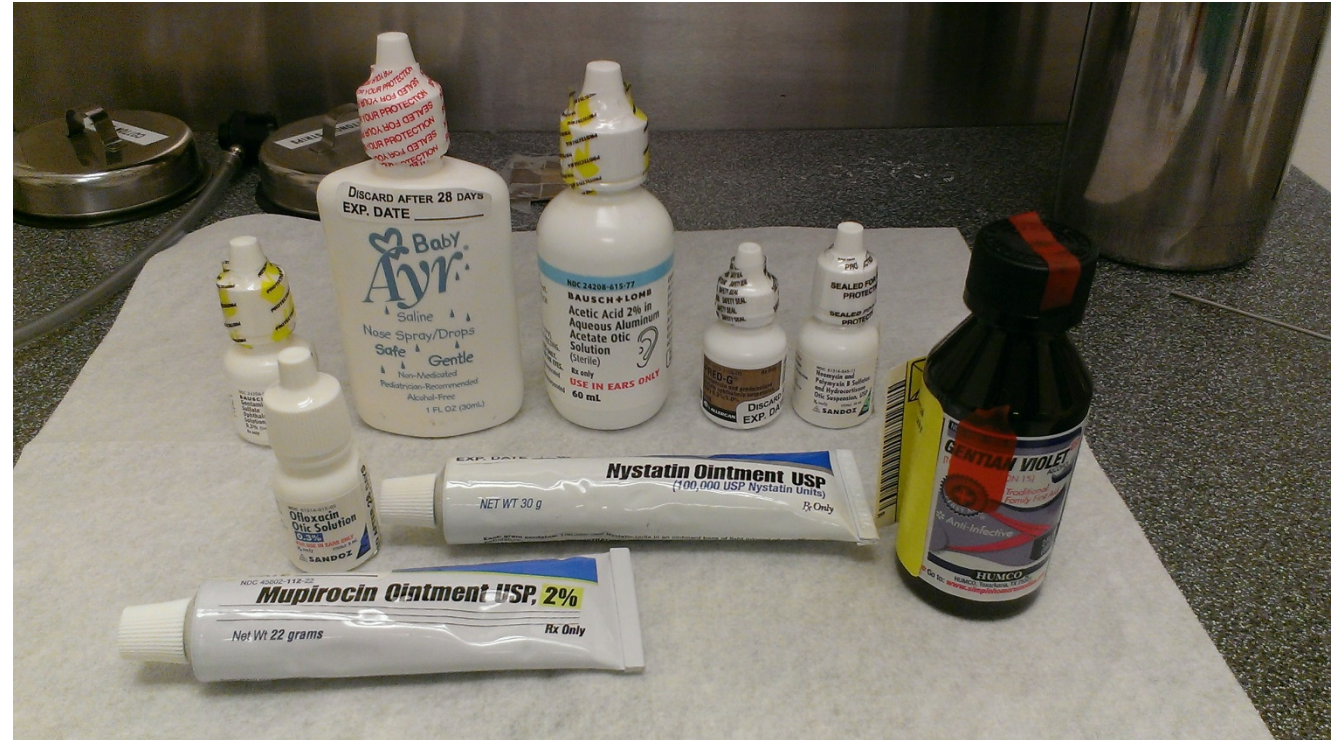# In the assessment of any draining ear

- Use something to clean the ear
- Teach the patient how to clean the ear
- Educate them to clean it prior to any drop application
- Cleaning is probably as important if not more important than medication
- Can't clean it too much
- Saline drops + cleaning and ½ strength vinegar + cleaning have been shown to be as effective as other treatments



# Fourth important concept for today

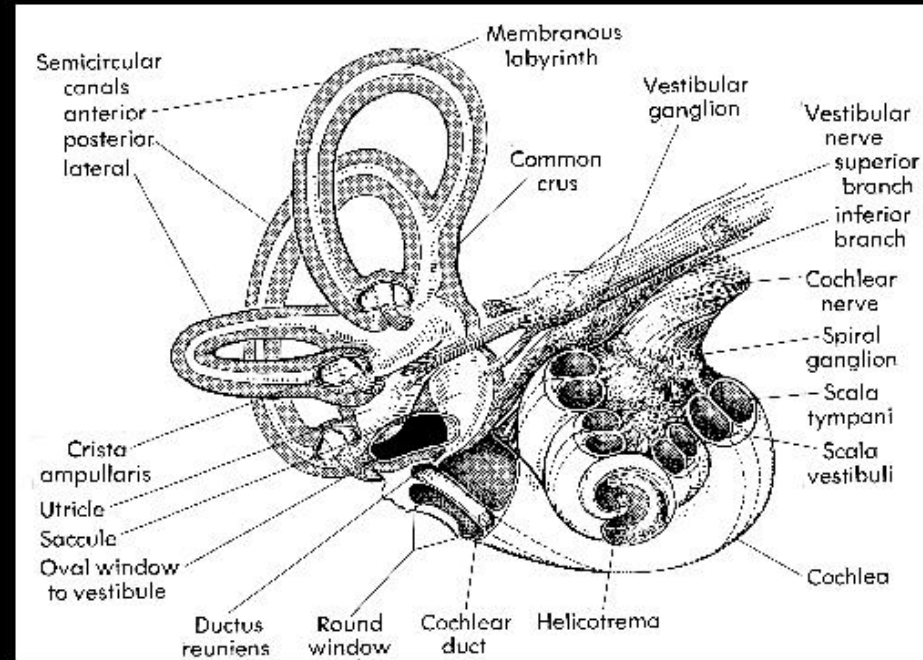
- All ear drops will work if you get them to the infected tissue (because of the high concentration)
- **DO NOT USE AN OTOTOXIC EAR DROP IF THERE IS ANY CHANCE IT COULD MAKE IT INTO THE MIDDLE EAR SPACE**
- Safest and best to eliminate all of your ototoxic drops



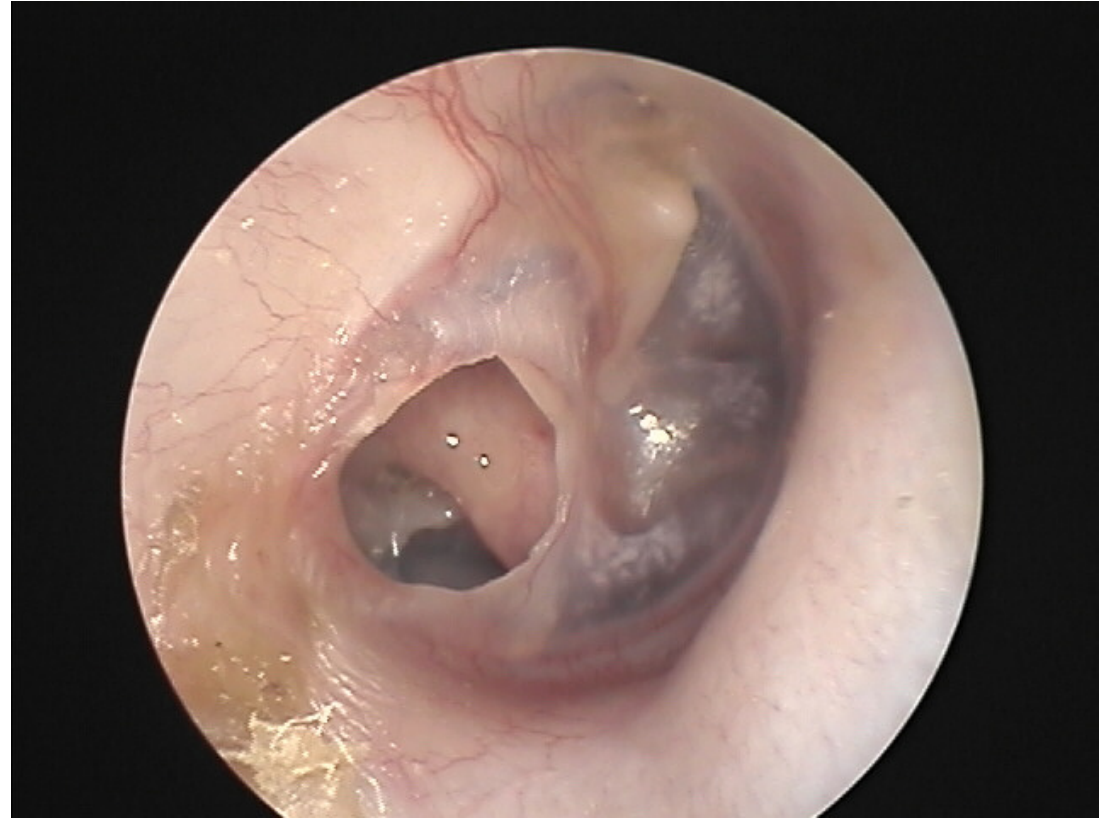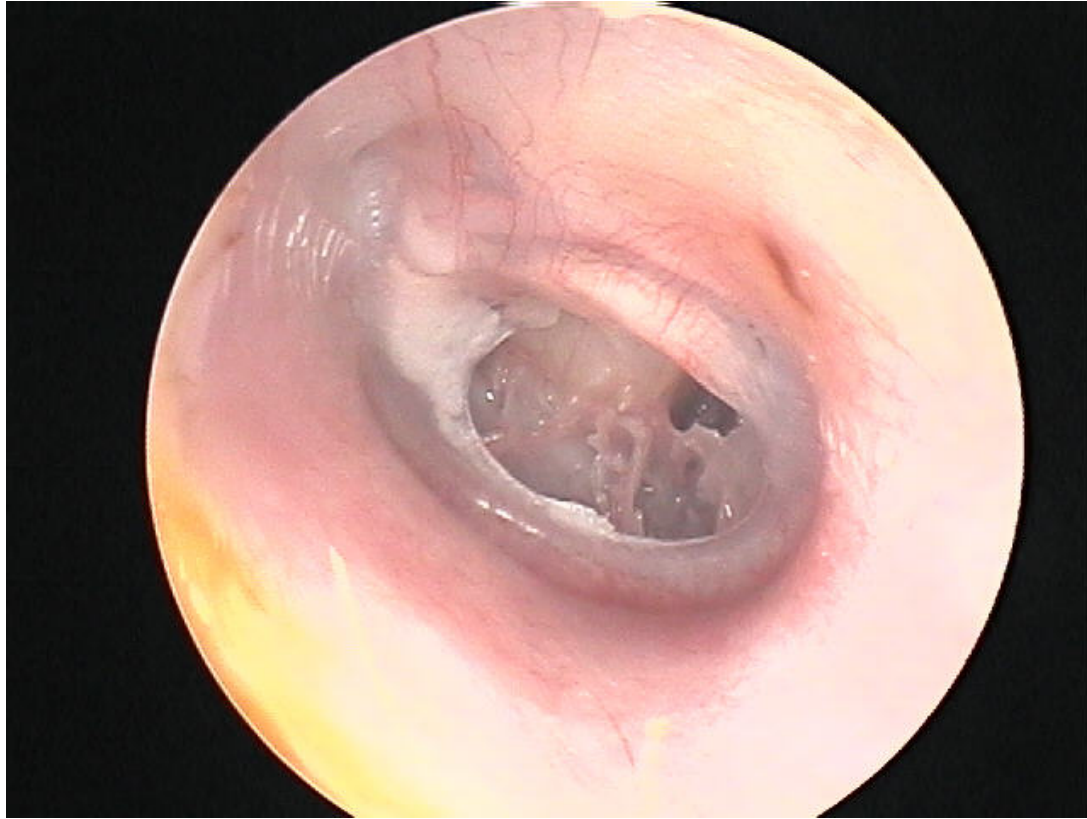
# Ototoxicity

- Any ear drop with tobramycin, gentamycin, neomycin is potentially ototoxic if it enters the middle ear space
- Quinolones are the only FDA approved ear drop
- Acetic acid has been found to be just as effective as antibiotic ear drops

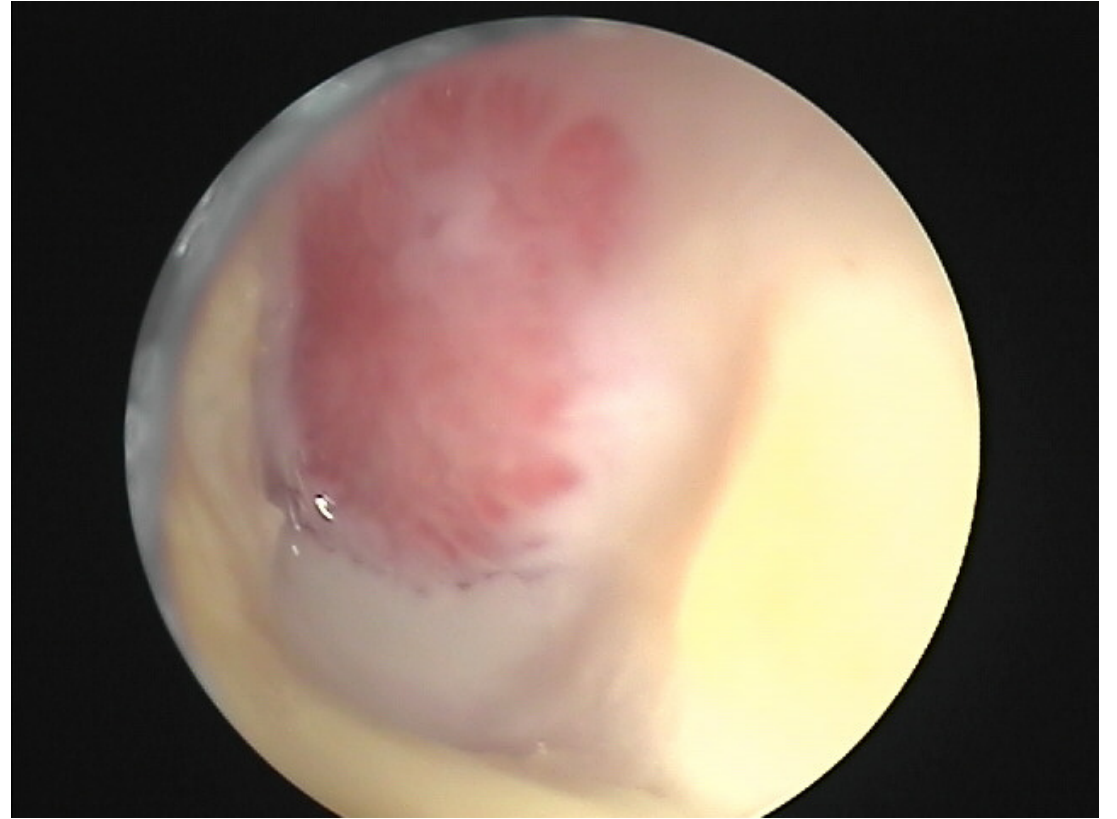
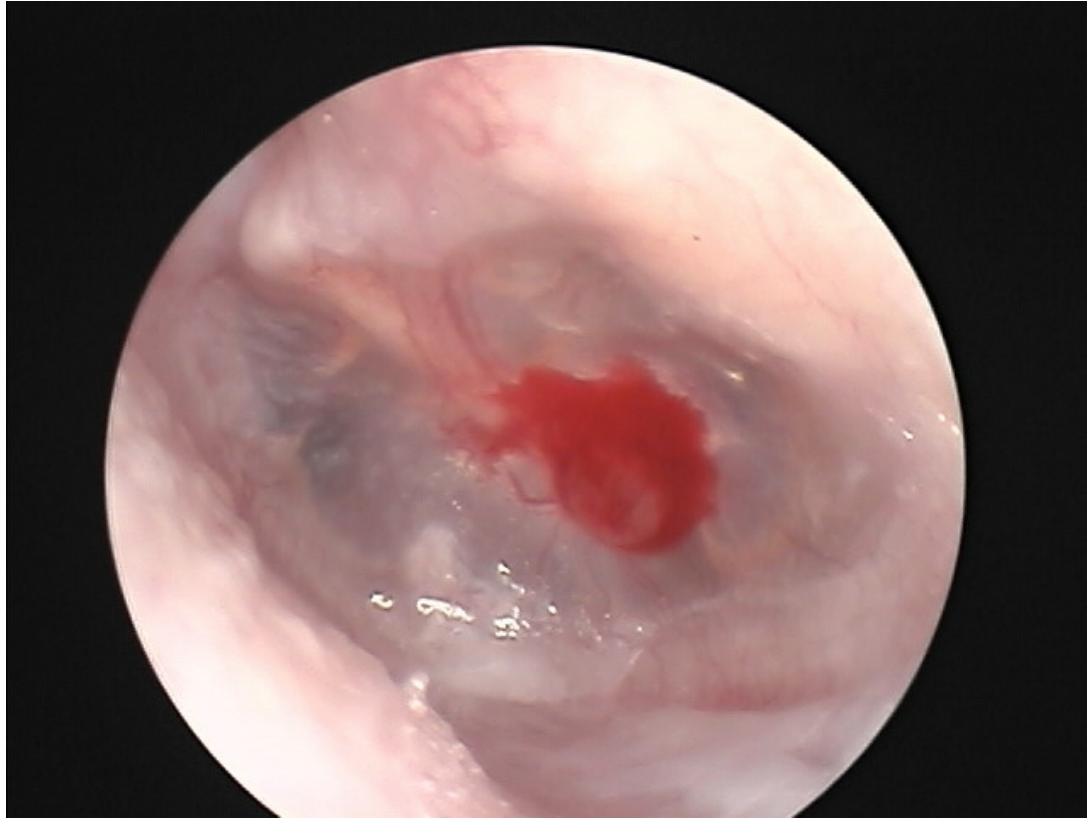*BCC Microimaging Inc.*



NO OTOTOXIC DROPS!!!!



OTOTOXIC DROPS ARE OK (But probably best never to use them)



# Topical antibiotics

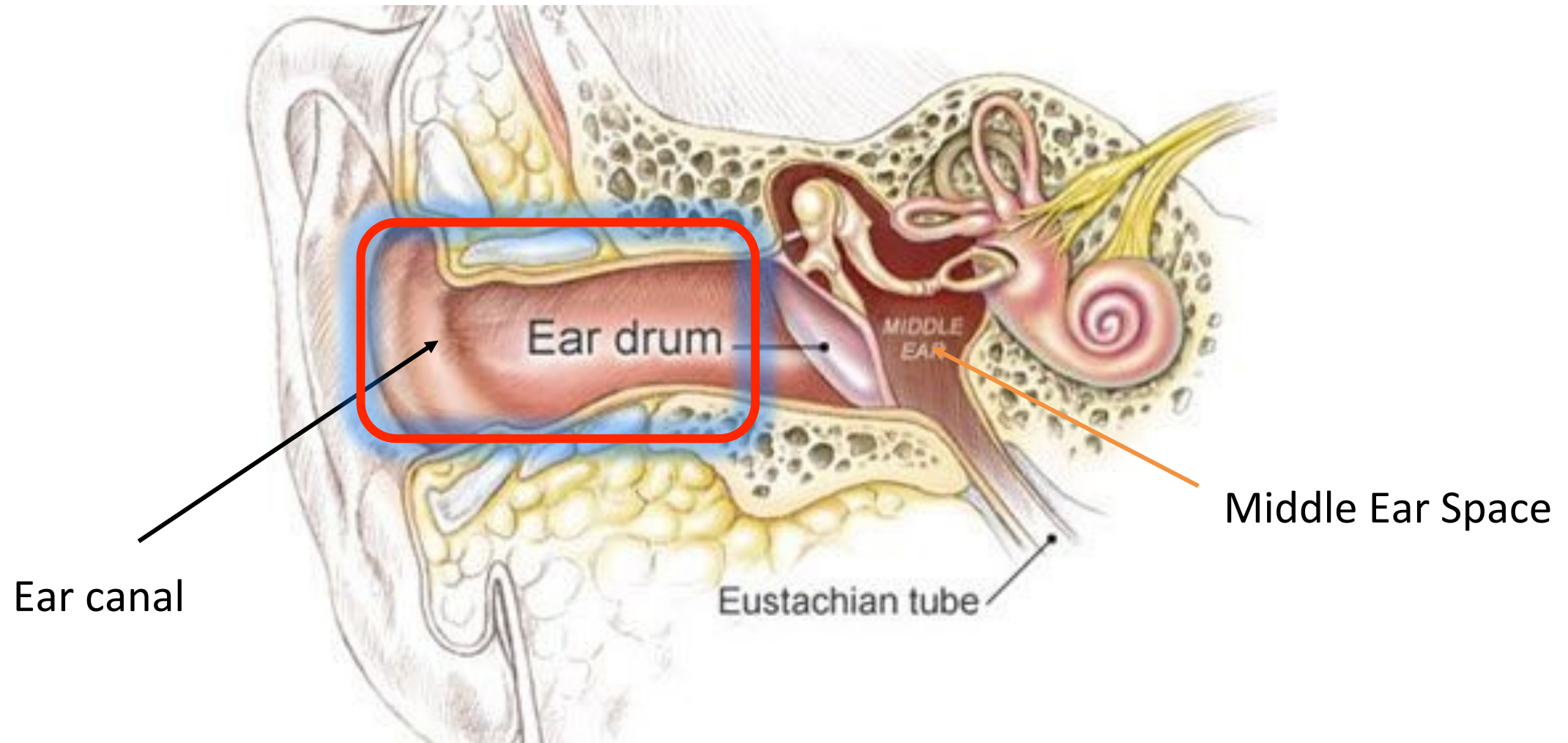
- Your choice of an ear drops is not as important as
  - Not using an ototoxic drop that has access to middle ear space (behind the ear drum)
  - Getting the drop in contact with the infected tissue by doing adequate and ongoing cleaning
  - This is why we don't culture draining ears



It's all about the concentration

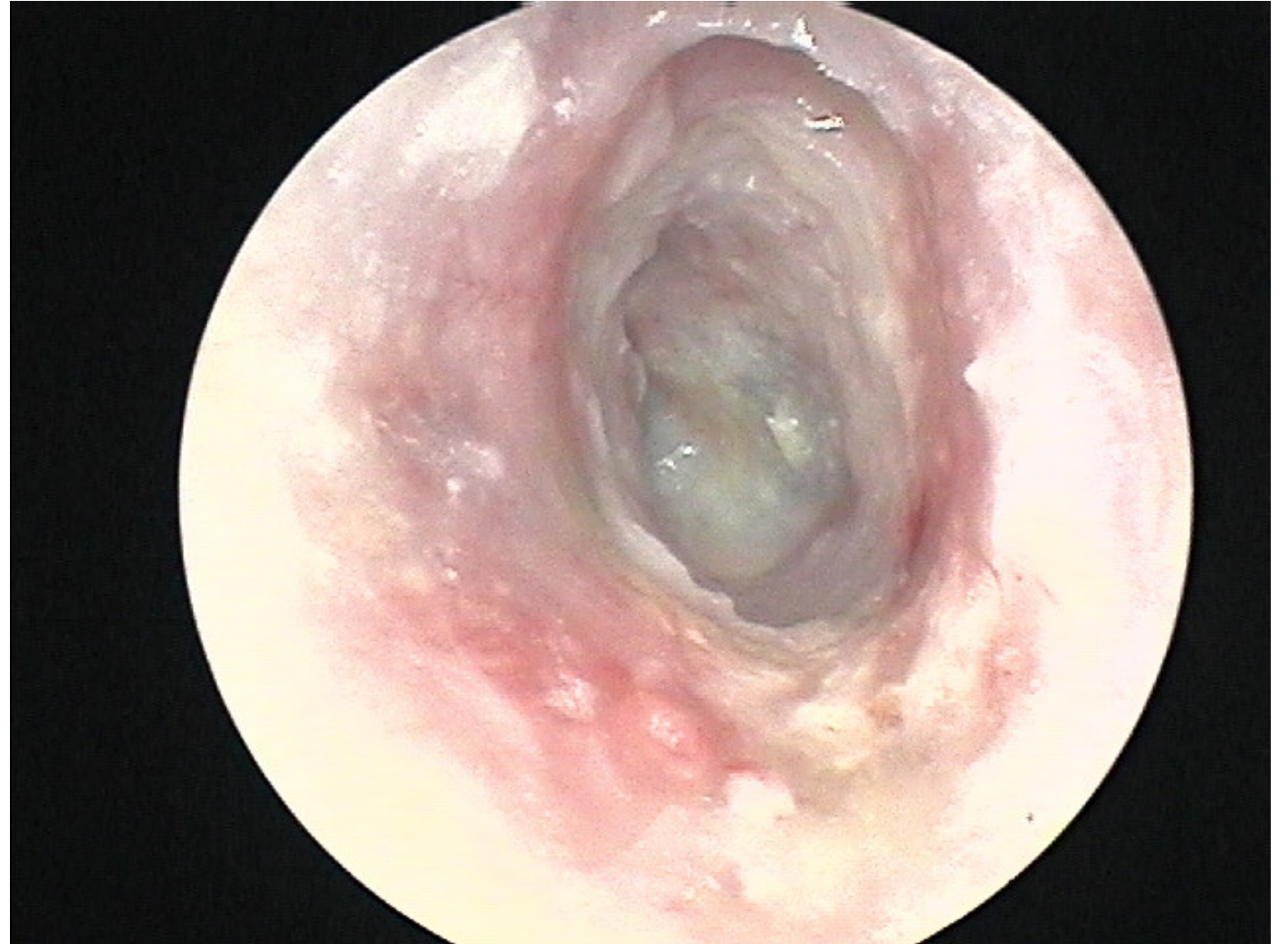


# Infections of ear canal

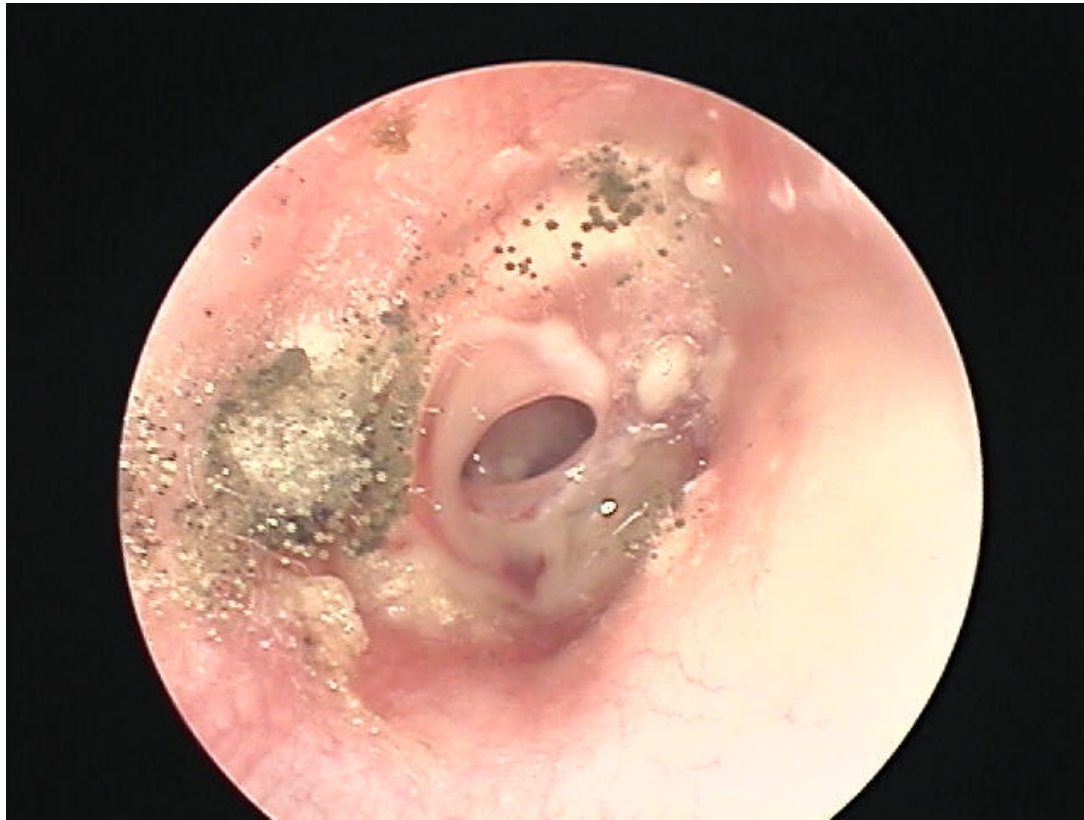

# Infections of ear canal

- Fungal otitis
- Acute otitis externa
- Chronic otitis externa
  - Skin condition

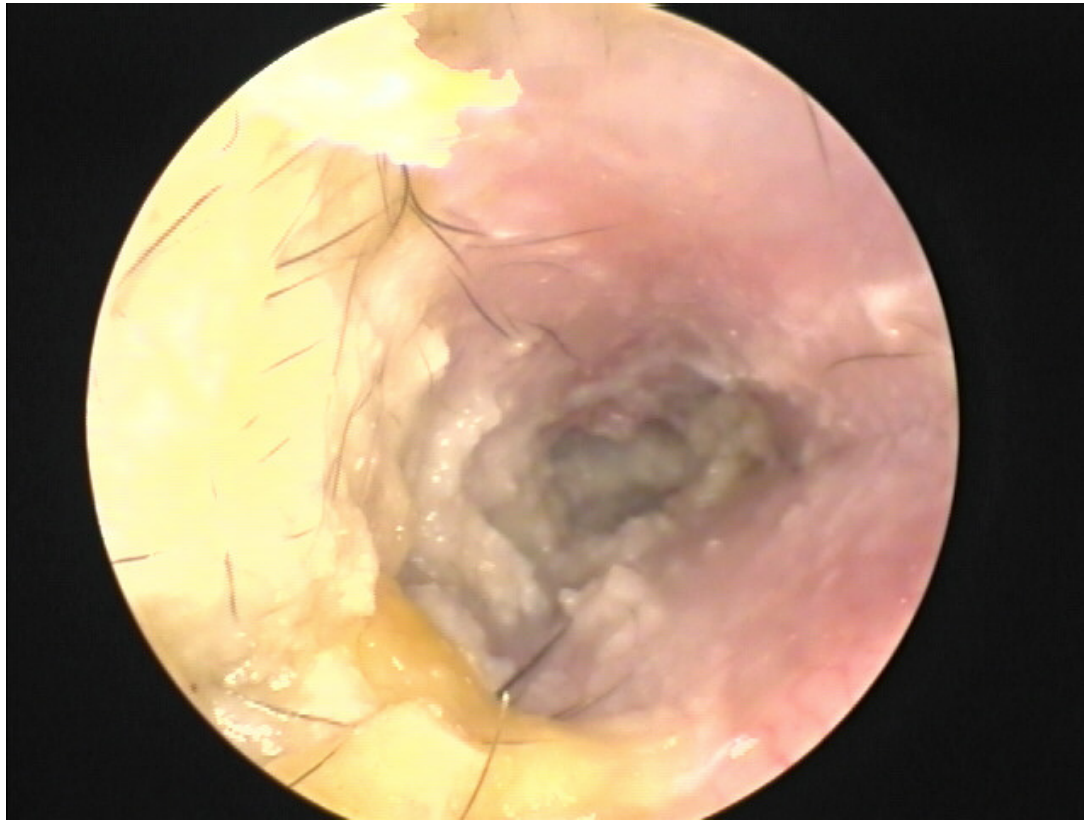


# Fungal otitis



- Clean the ear
- Acidify the ear
- Keep it dry
- Clean the ear

# Acute Otitis Externa



- Clean the ear
- Topical antibiotic drop + steroid
- Acidify the ear
- Pain control if necessary
- Keep ear dry
- Put wick in ear (pope wick)
- Systemics if spread to soft tissue

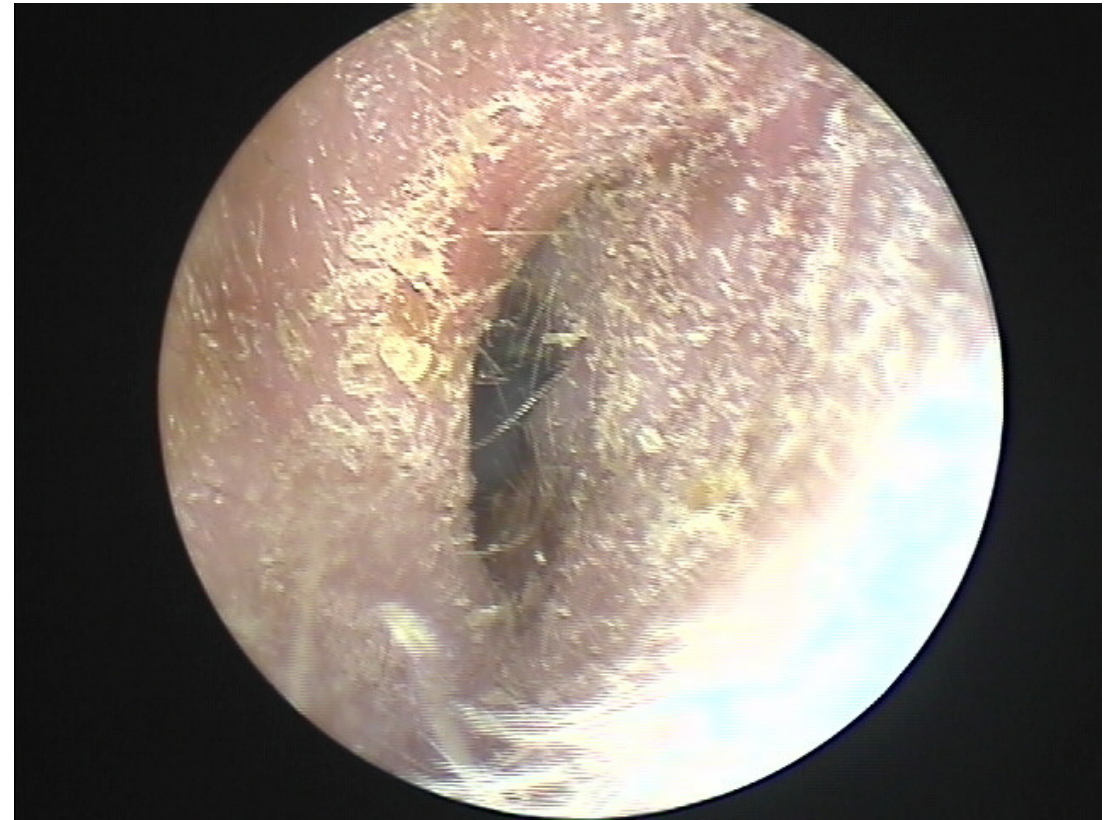# Pope Wicks



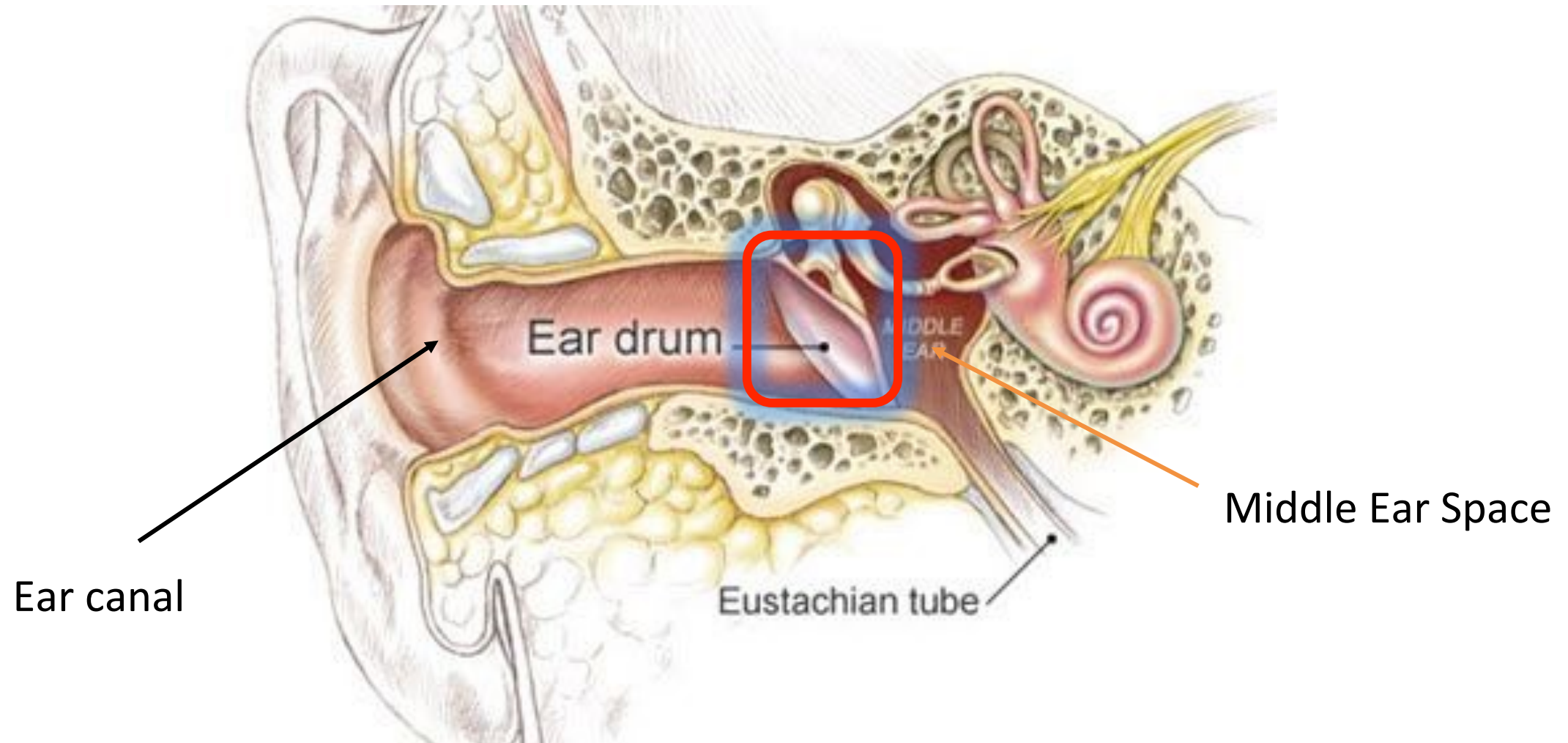- Expandable sponge
- Holds medication in place
- Expands canal
- Must be removed

# Chronic otitis externa

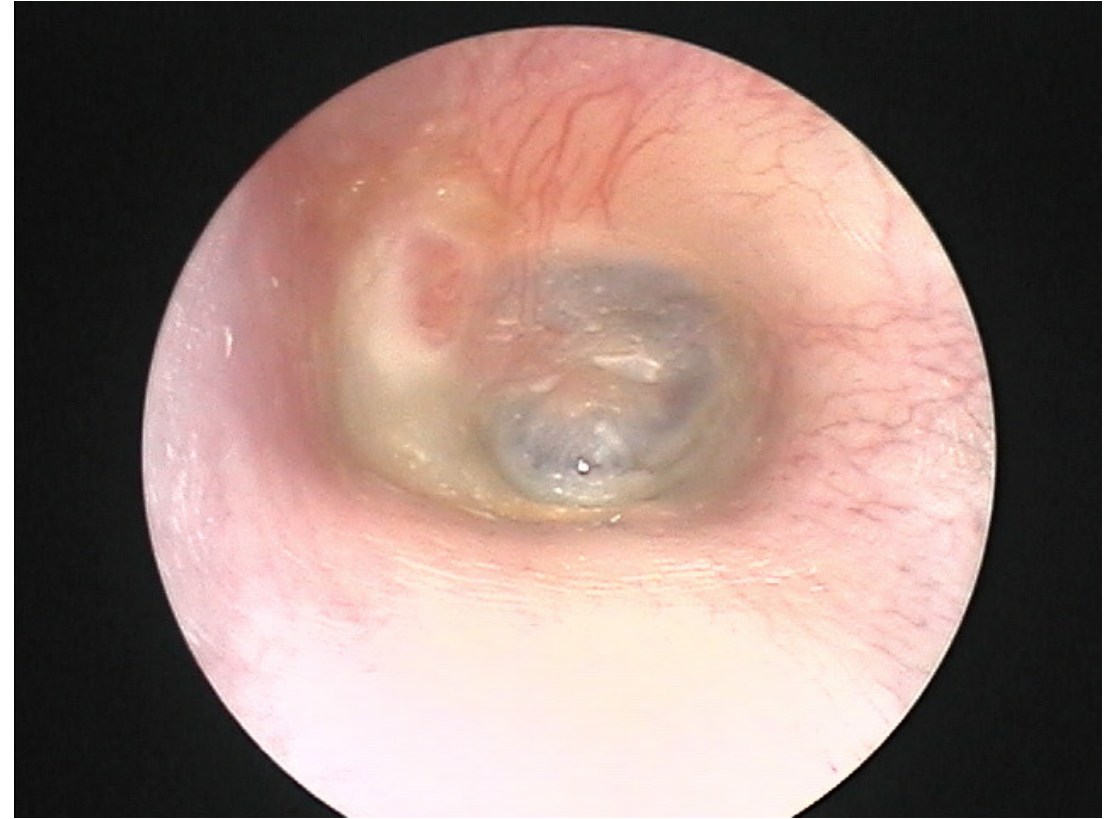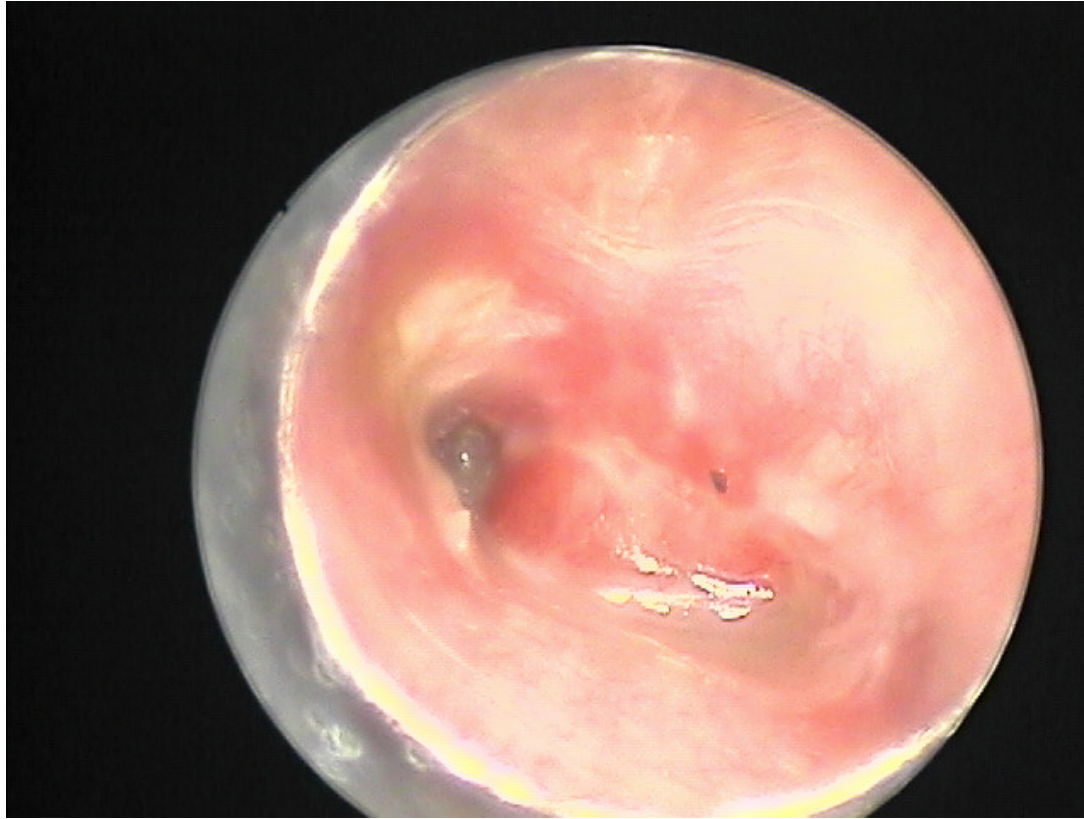
- This is a dermatology problem that makes ear prone to acute otitis
- Keep ear dry
- Topical steroid cream for maintenance
- ABX/steroid combo for acute stage

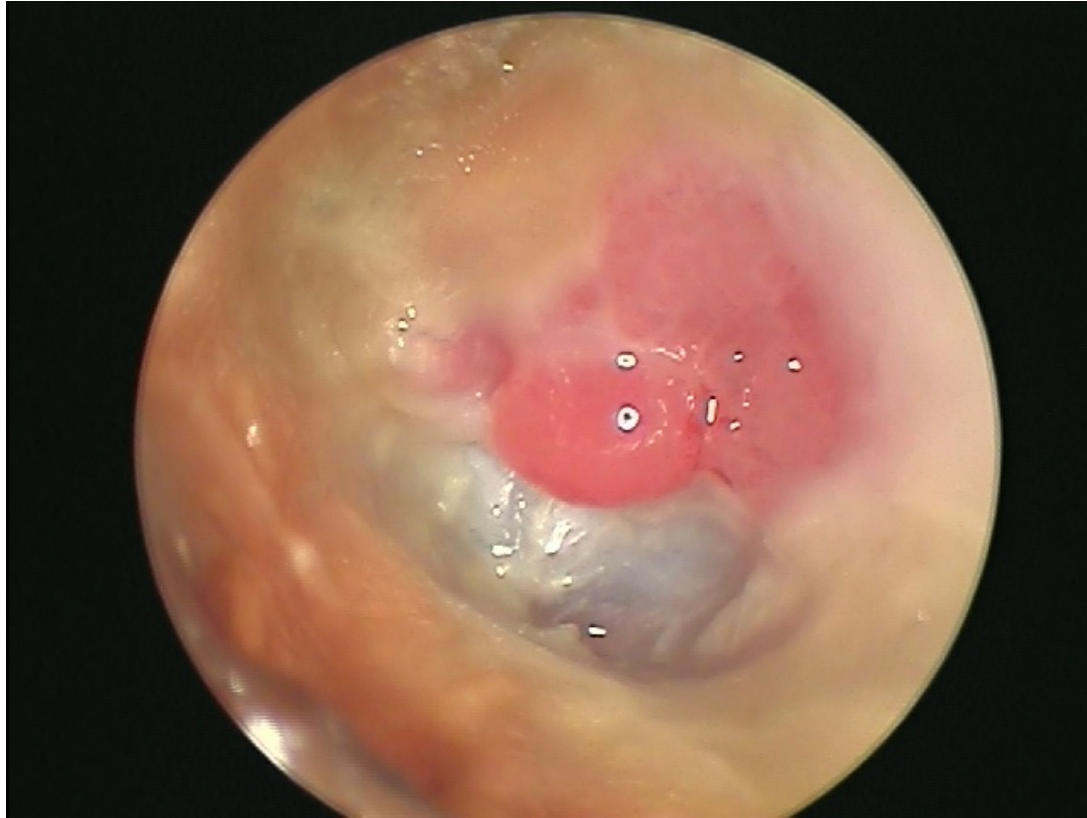

# Infections of TM surface

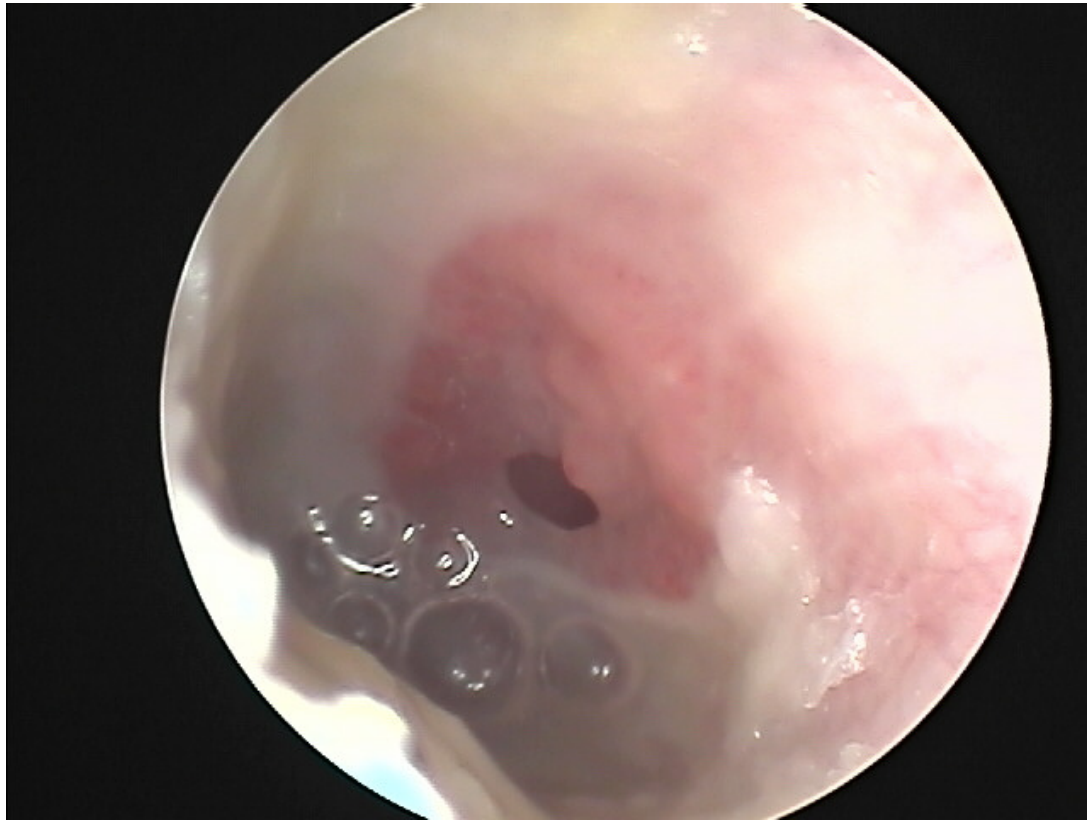

# Infections of the TM

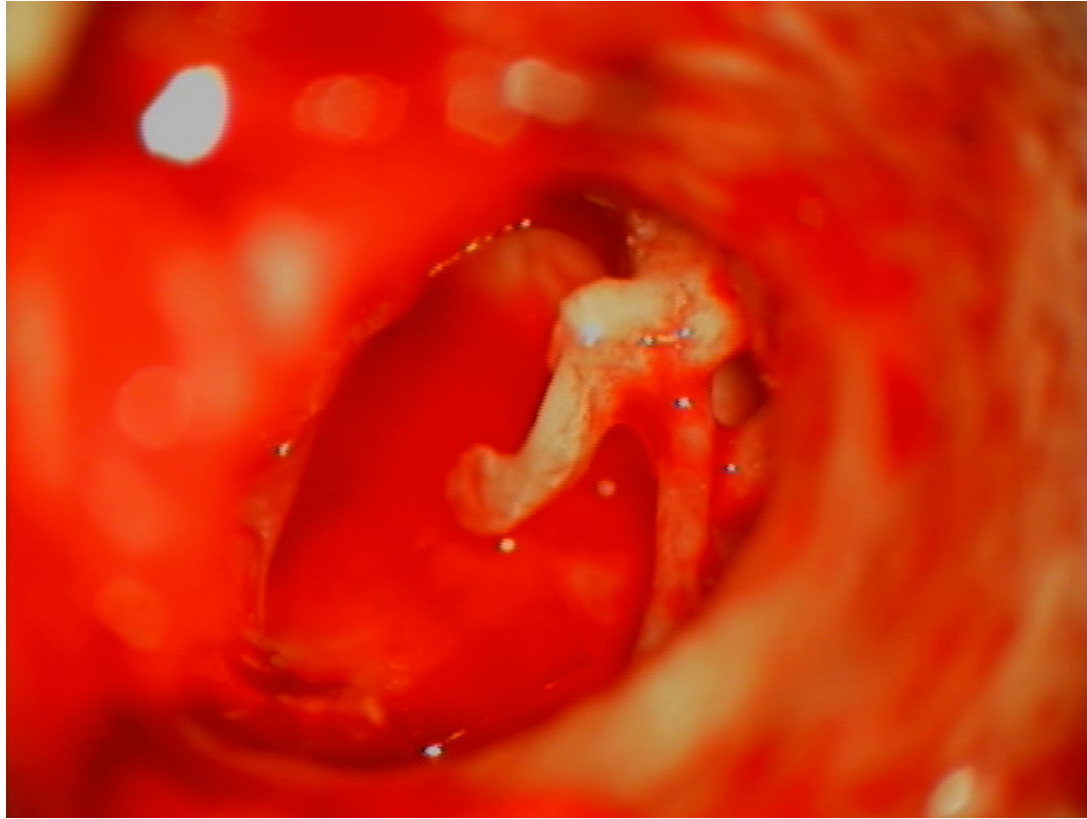




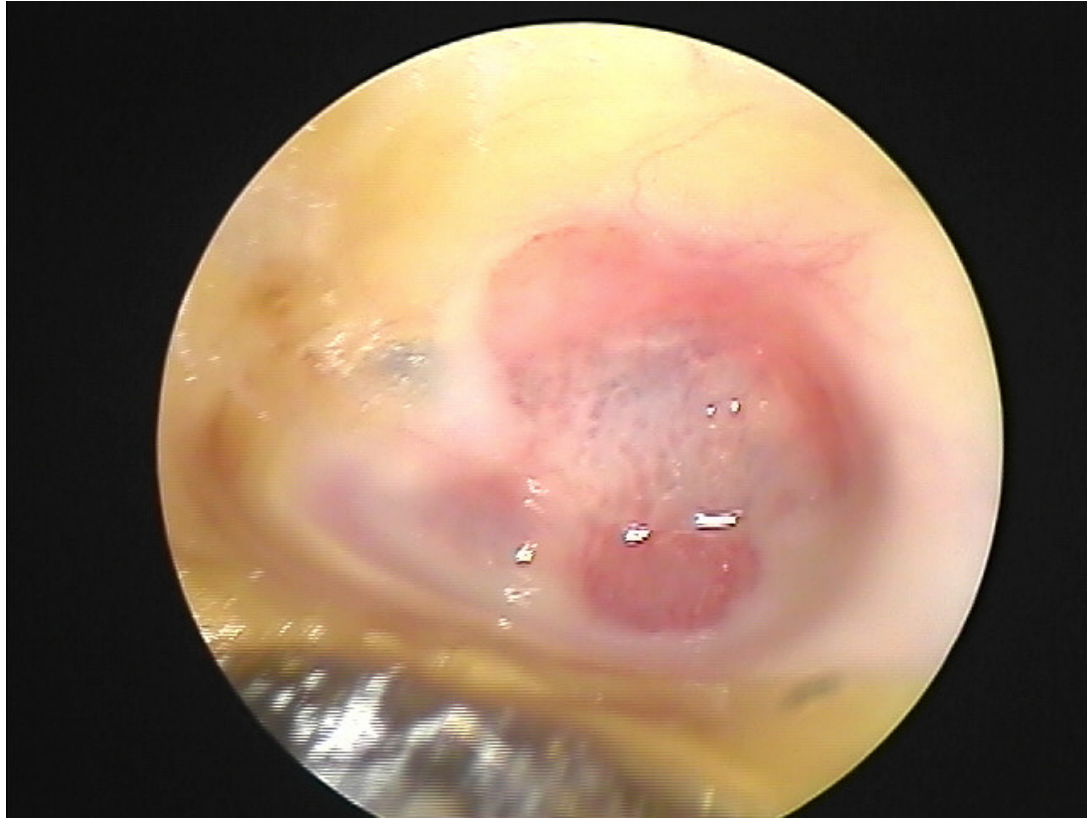- These are infections on the surface of TM
- Cleaning
- Topical drops – ABX+steroids
- Acidify ear
- Severe case may require debridement by ENT
- Gentian violet/boric acid



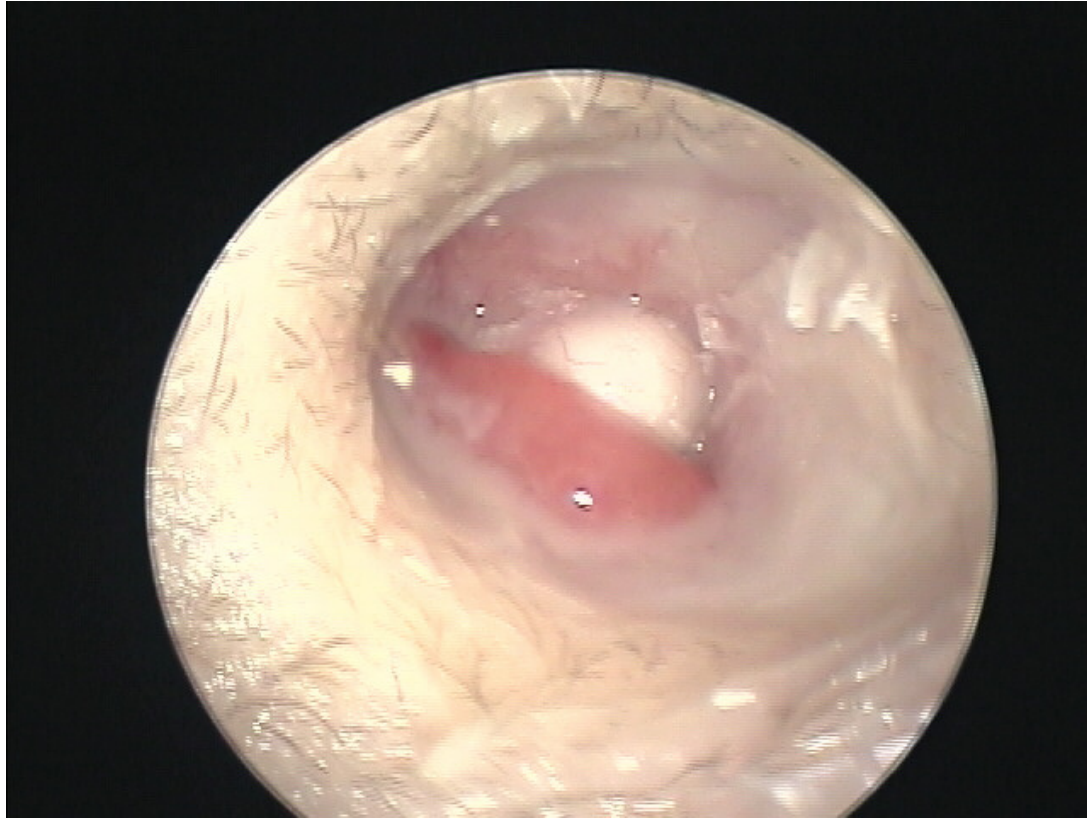- In most cases probably OK to use ototoxic drop, but must be confident that there is no perforation



- Ototoxic drops in middle ear space can lead to irreversible hearing loss
- You won't be able to prove a neurosensory hearing loss did not come from them
- I'd get rid of them

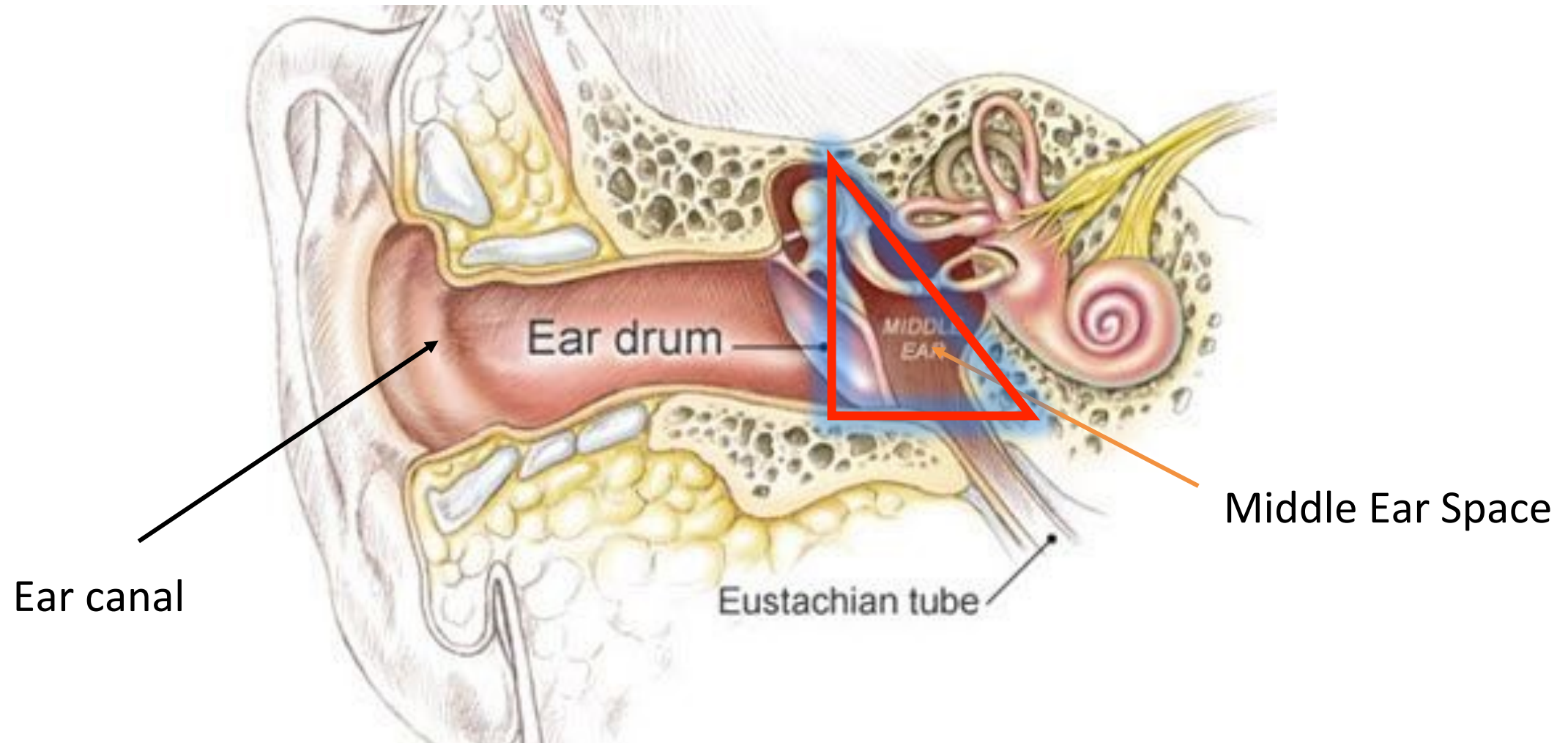


- In severe cases, entire TM may need to be removed and replaced.

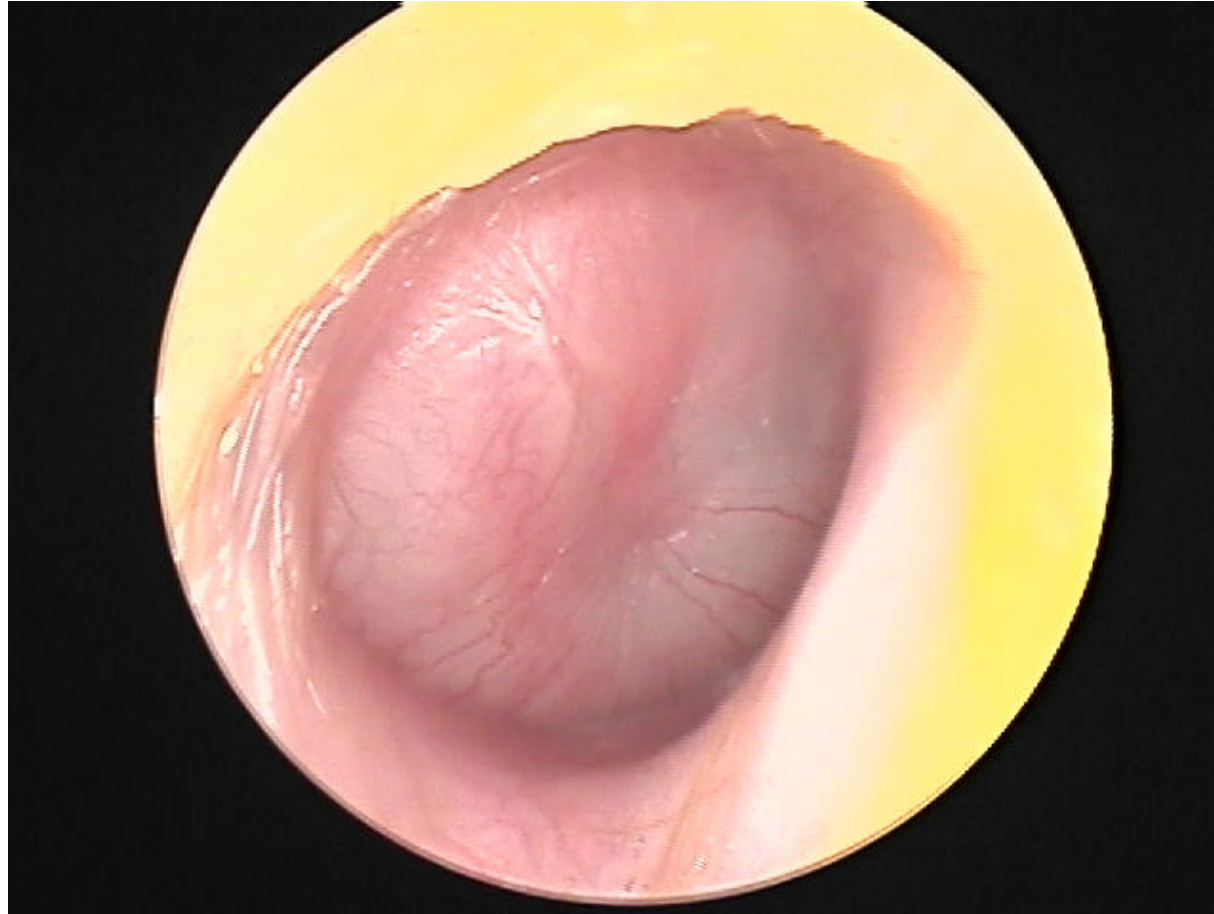


- Always re examine after treatment.
- Cholesteatoma can be present beneath granulation tissue

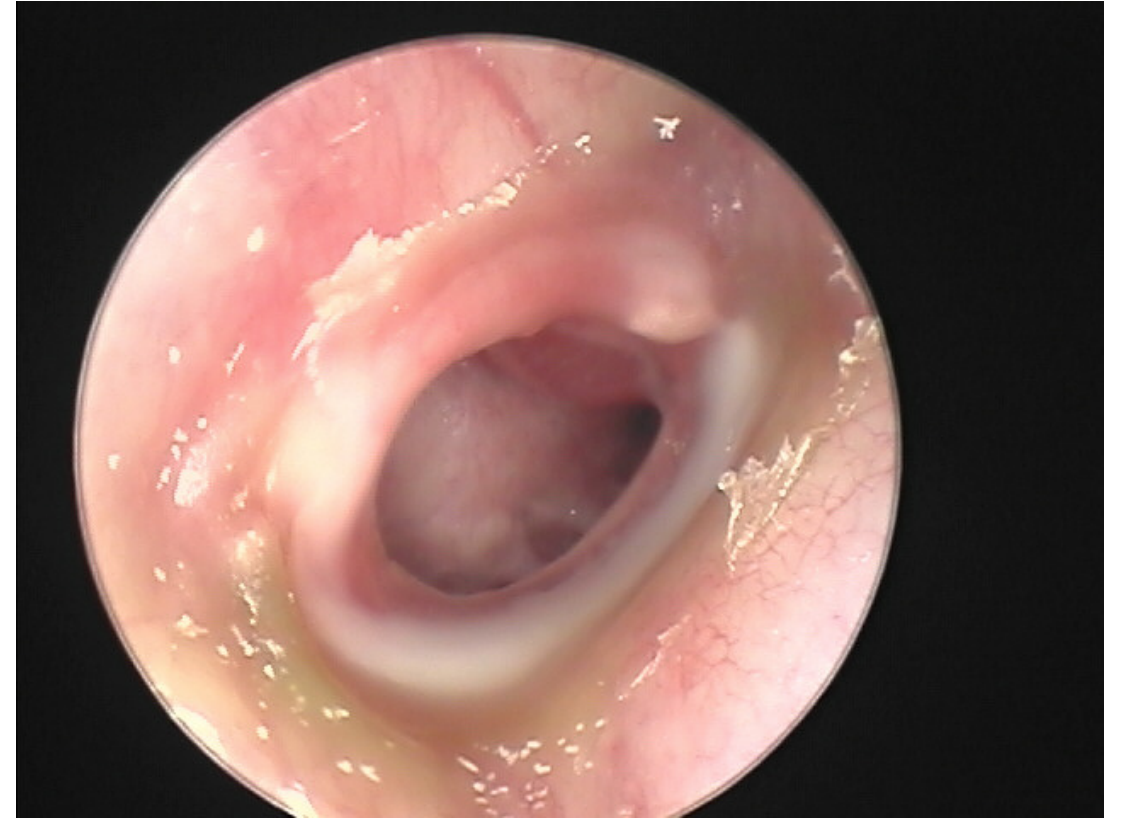
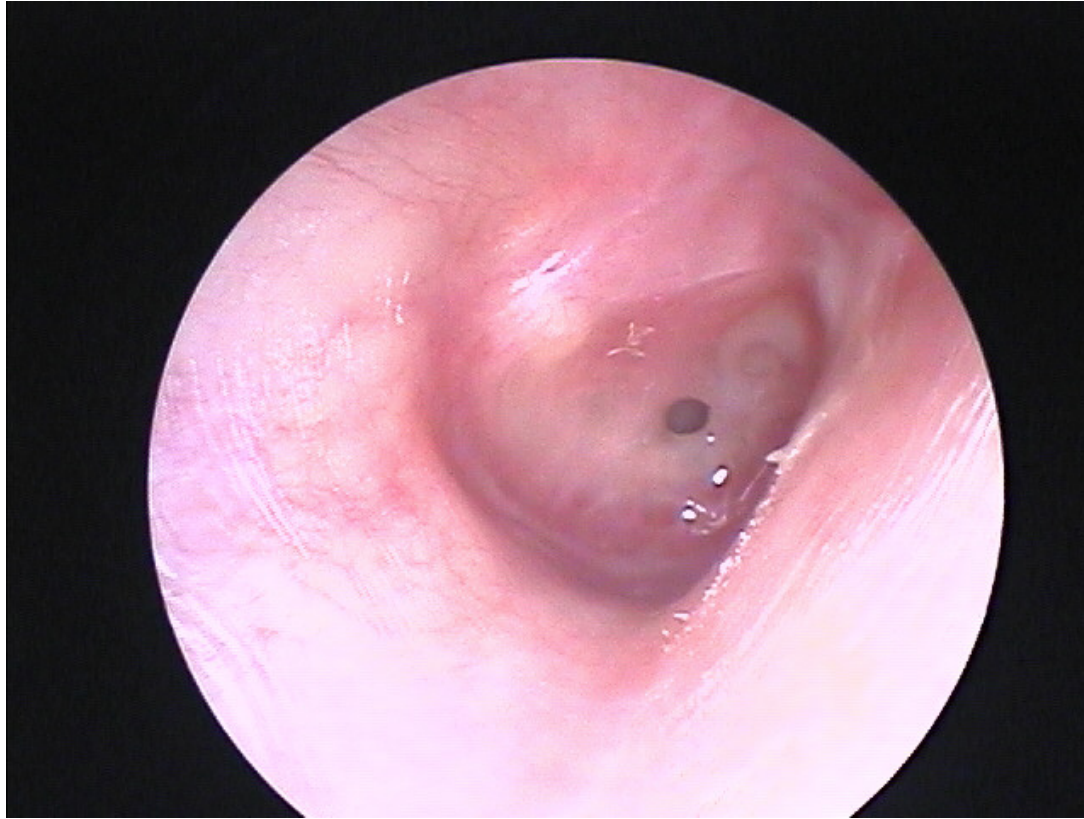
# Infections of middle ear



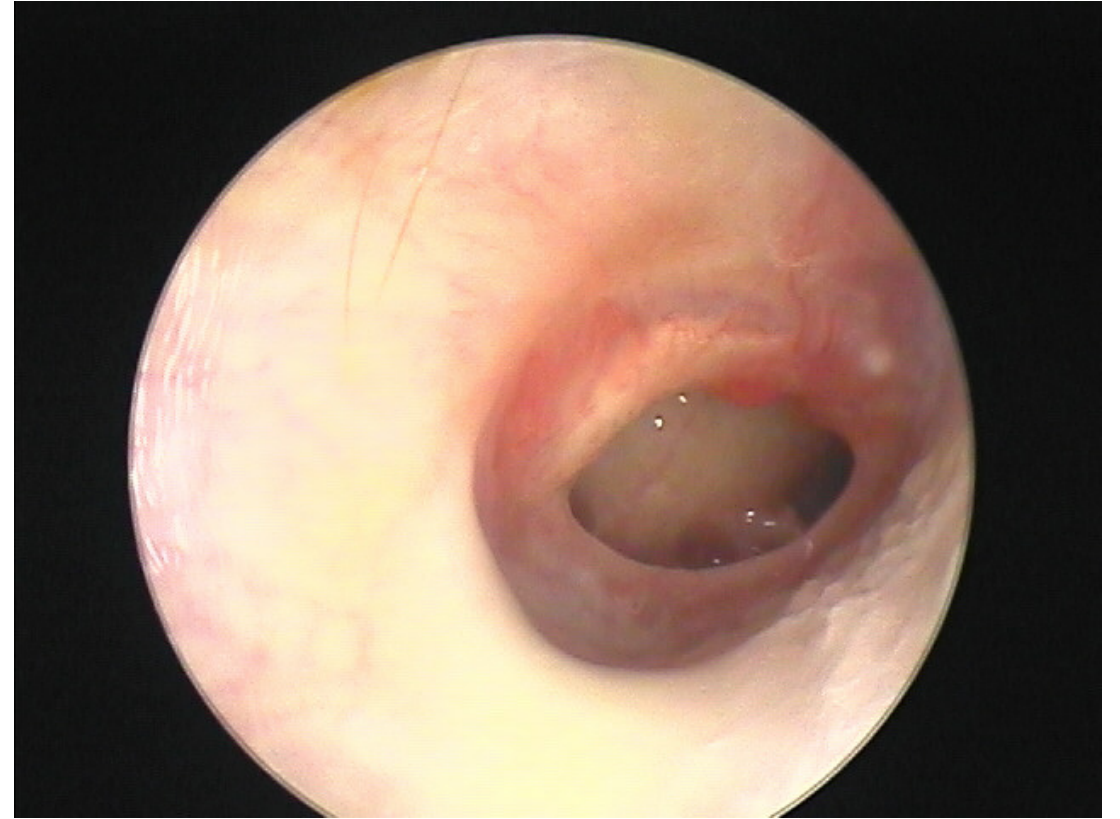
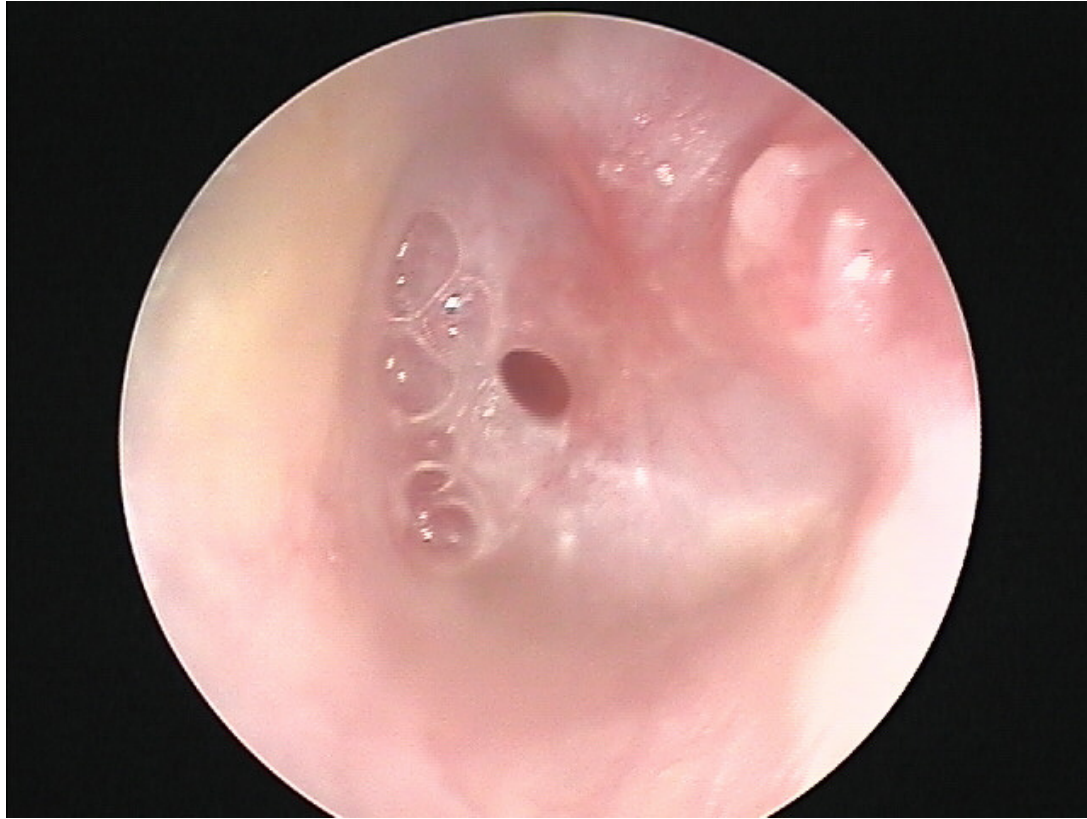
# Infection of middle ear space

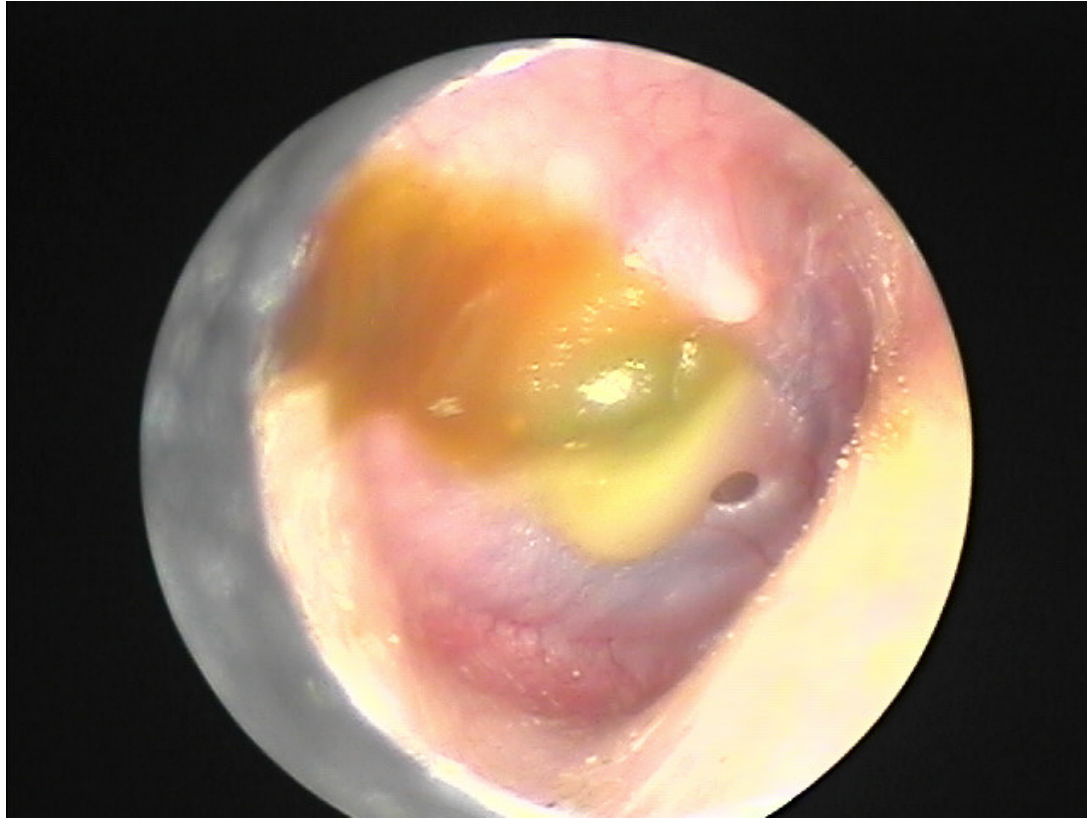


You need to differentiate these two as distinct entities

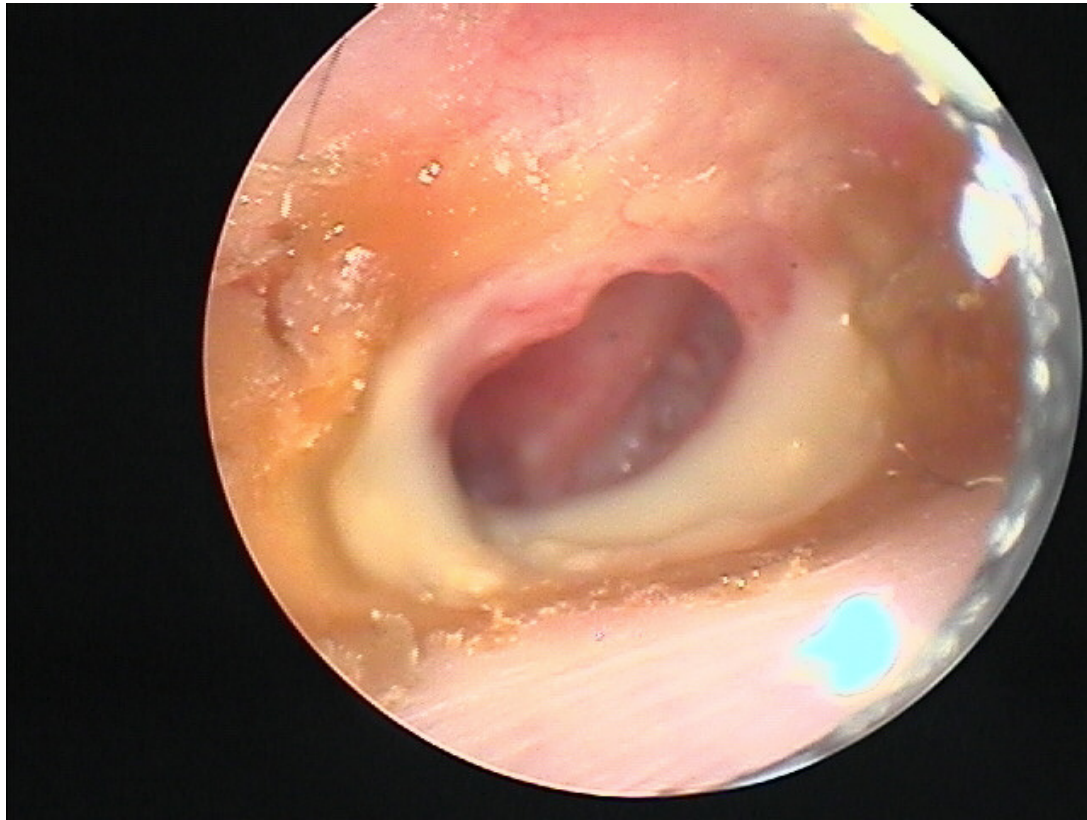


Topical drops are best, but can they make it into the middle ear?

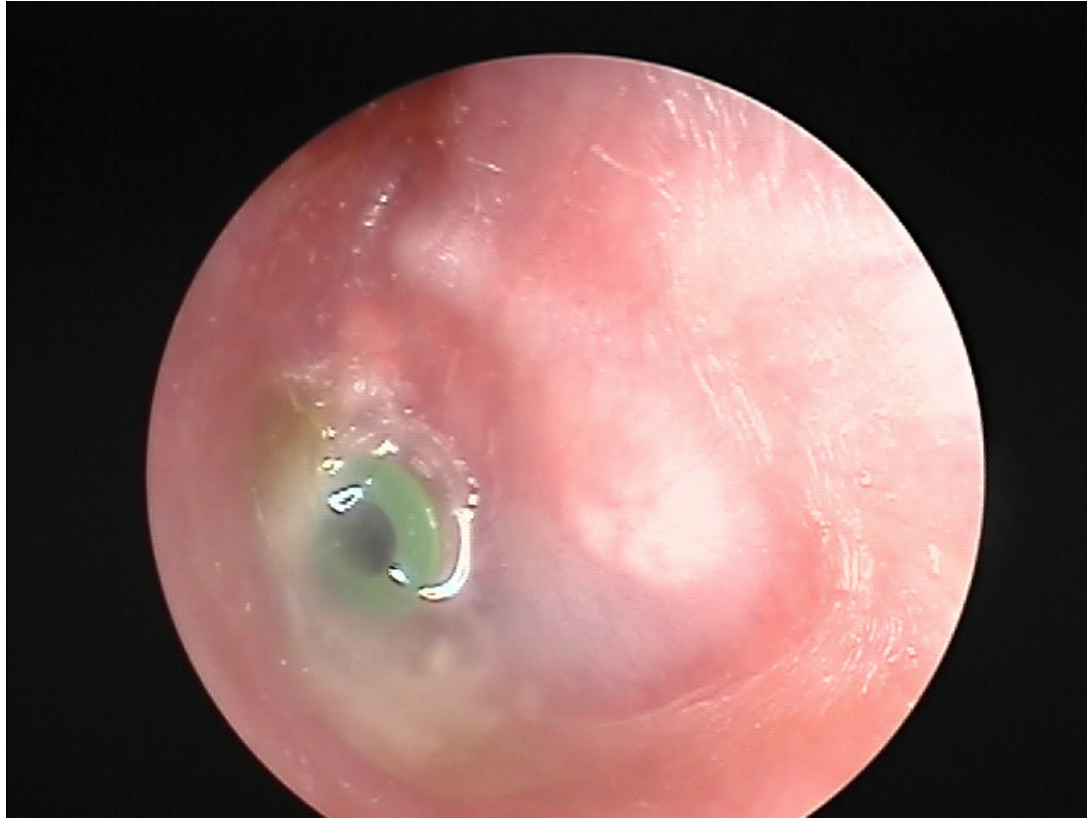



- Tiny perforations
- Drops won't make it into ME
- Treat like AOM
- Add drops if TM or canal looks infected

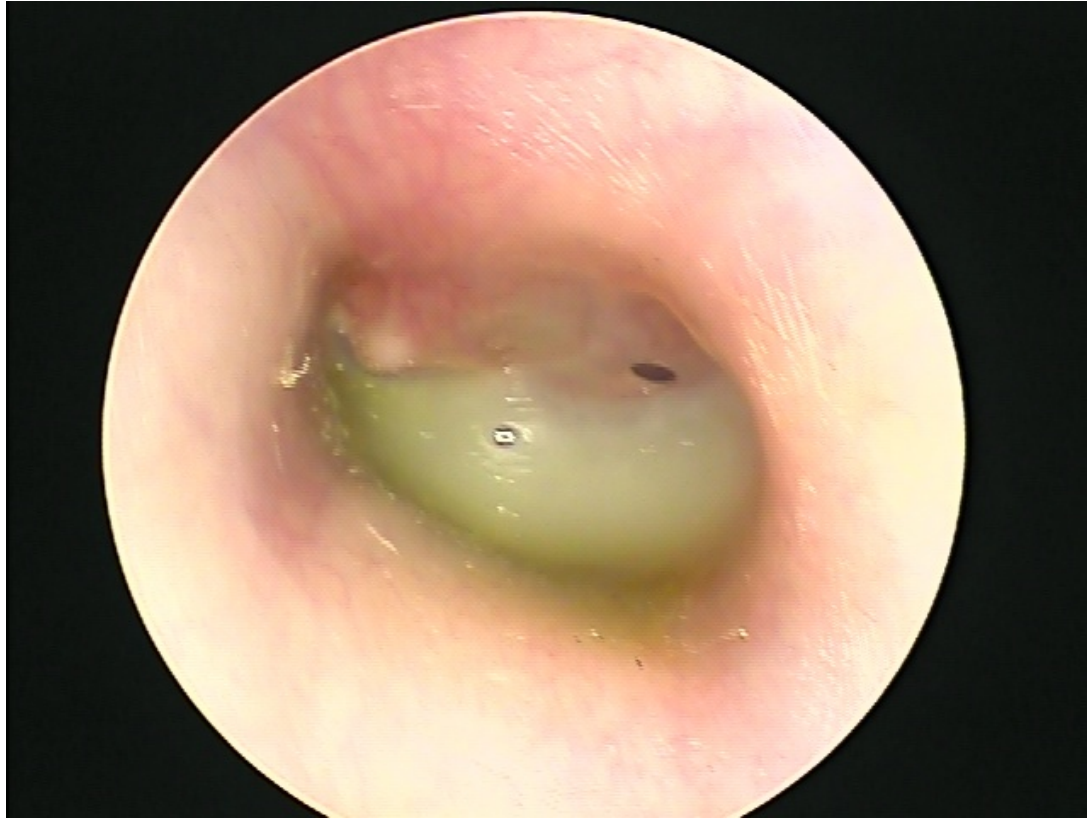

- Drops will easily make it to infected area (middle ear)
- Clean ear
- Topical drops
- Keep ear dry
- Re examine
- Systemic abx not necessary unless there is soft tissue involvement



- Consider ear tube large enough to admit drops
- Proper technique – clean ear and use tragal pump
- Suctioning if possible
- Systemic abx if not making progress (treat like AOM)

# Summary



- Concepts more important than details
- Always clean the ear
- Think about where the infection is coming from and how to get the highest concentration of medication to the affected area
- Always clean the ear
- Topical drops always better than systemics
- Get rid of your ototoxic drops
- Always clean the ear